



# CASE PRESENTATION

**Sana S. Siddique<sup>1'2</sup>, C. Stephen Foster<sup>1'2</sup>**

*<sup>1</sup>Massachusetts Eye Research and Surgery Institution (MERSI), Cambridge, MA*

*<sup>2</sup>Ocular Immunology and Uveitis Foundation*

# History of Presenting Illness

54 year old Caucasian female with recurrent unilateral redness and irritation OS

4-5 episodes over 4 years treated with Tobradex

No workup, systemic treatment, or IMT specifically for ocular symptoms

1 month of redness and irritation prior to initial presentation at MERSI

# Past Medical History

## Cutaneous pemphigus vulgaris

Diagnosed by skin biopsy in 2004

Extensive esophageal involvement initially

Numerous treatments:

- multiple courses of oral Prednisone
- CellCept,
- Rituxan and IV-Ig (since 2005)

Currently in remission on Rituxan and IV-Ig

## Depression

Paroxetine

## Recurrent genital herpes

Systemic Acyclovir



# Initial Examination

VA sc 20/20 OD, 20/25 OS

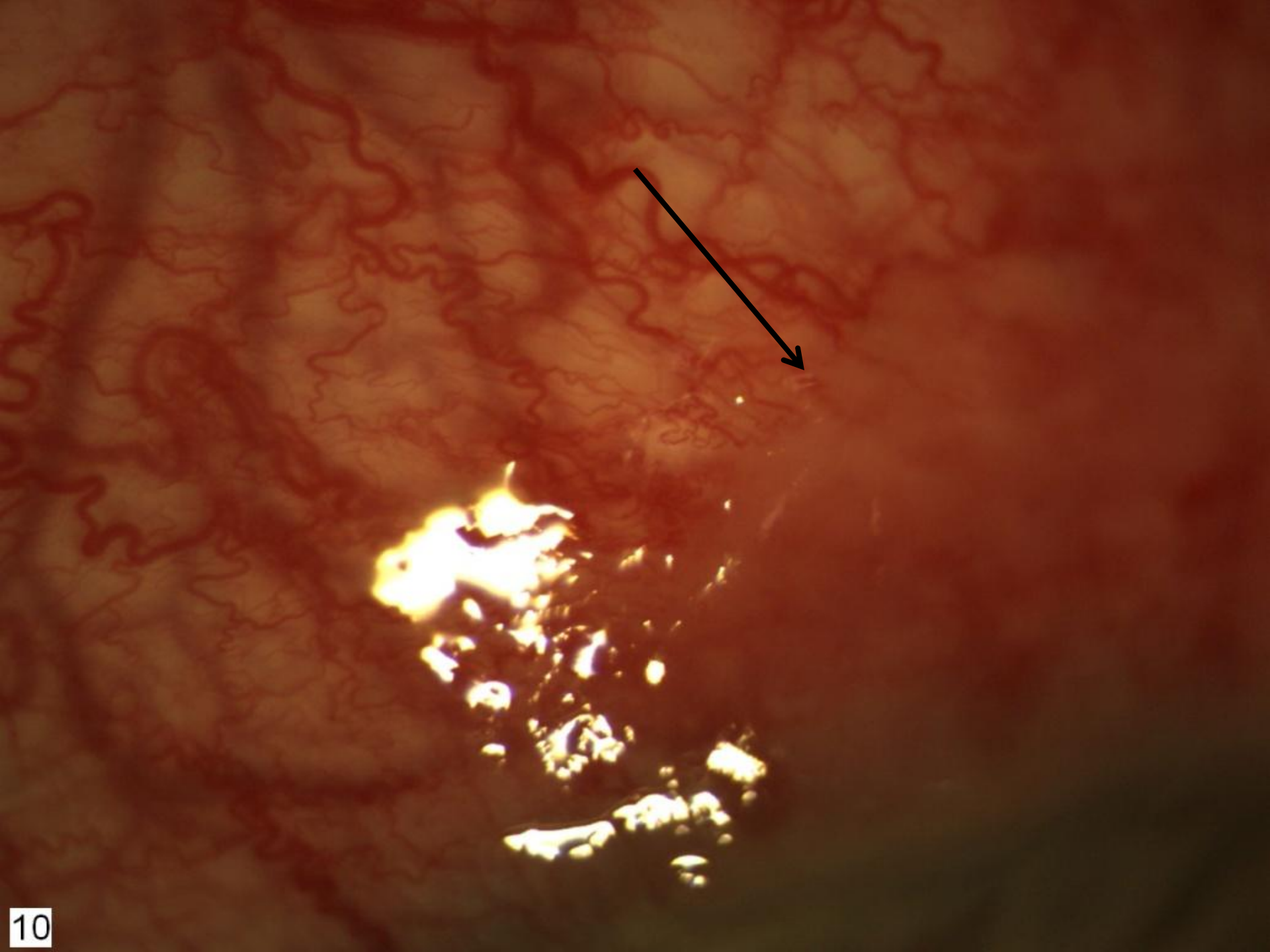
Pupils 4>2 OU, no RAPD

CVF full OU



EOM full OU

IOP 20mmHg OU



Exam	OD	OS
Lids	WNL	WNL
Conjunctiva/Sclera	White & quiet	<b>Diffuse 1+ injection with 3+ superficial &amp; deep vessel injection superiorly with a central white opacity</b>
Cornea	Clear	Clear
Anterior Chamber	Deep and quiet	Deep and quiet
Iris	Round and reactive	Round and reactive
Lens	<b>PSC</b>	<b>PSC</b>



# PLAN???

Serologies

Conjunctival & Scleral biopsy for  
Immunohistochemical staining



# Laboratory Studies

HLA typing

ACE

Lysozyme

ESR, CRP

C<sub>3</sub>, C<sub>4</sub>, CH<sub>50</sub>,

RF

Properdin factor 3

Bartonella henselae &  
quintana IgG/IgM

Hepatitis B

ANCA

Antibody testing:

SSA

SSB

SS-DNA

DS-DNA

Smith





# Laboratory Studies

IgE : 298 (<114 normal)

ANA : positive

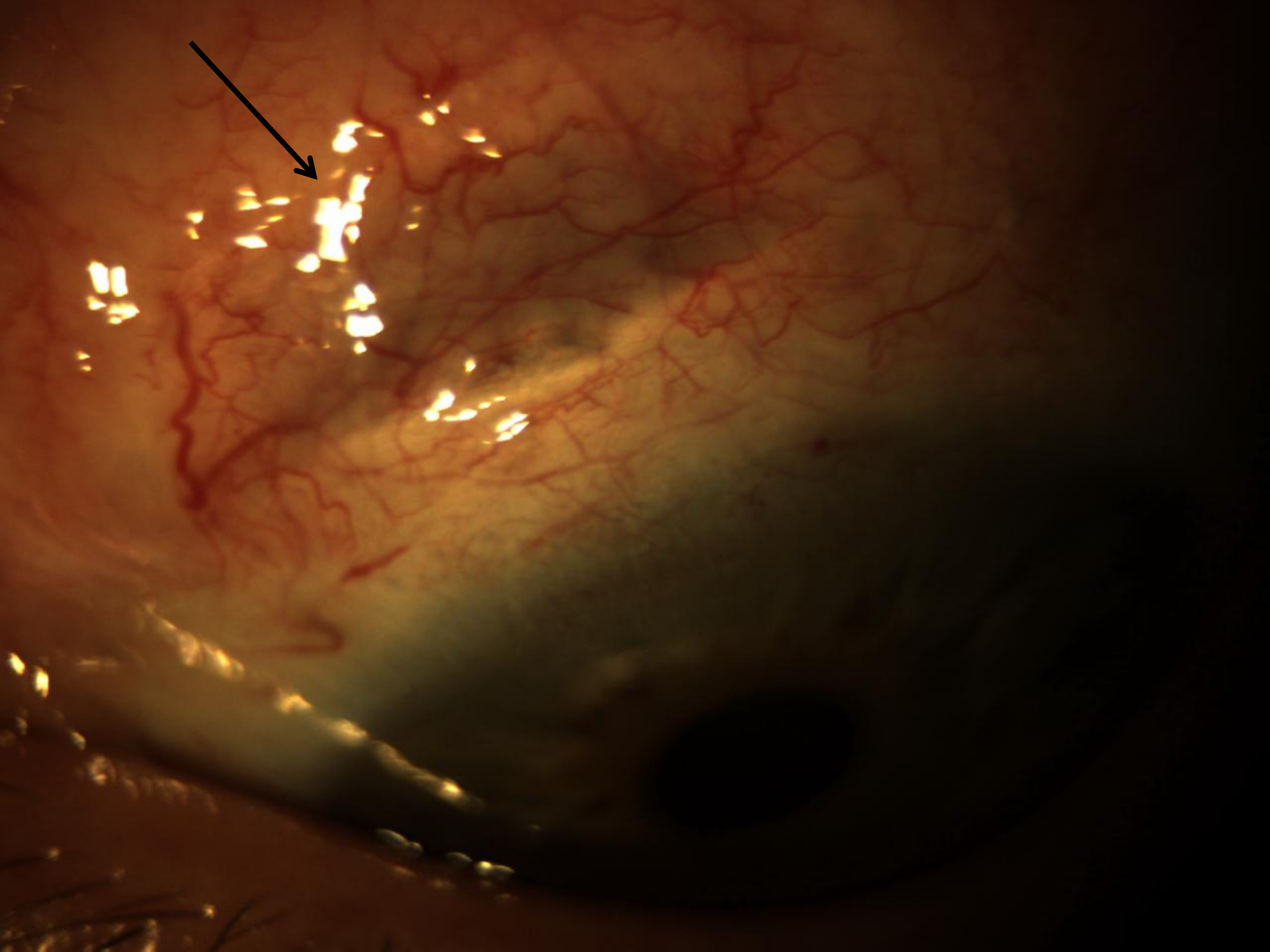
Titer 1:160

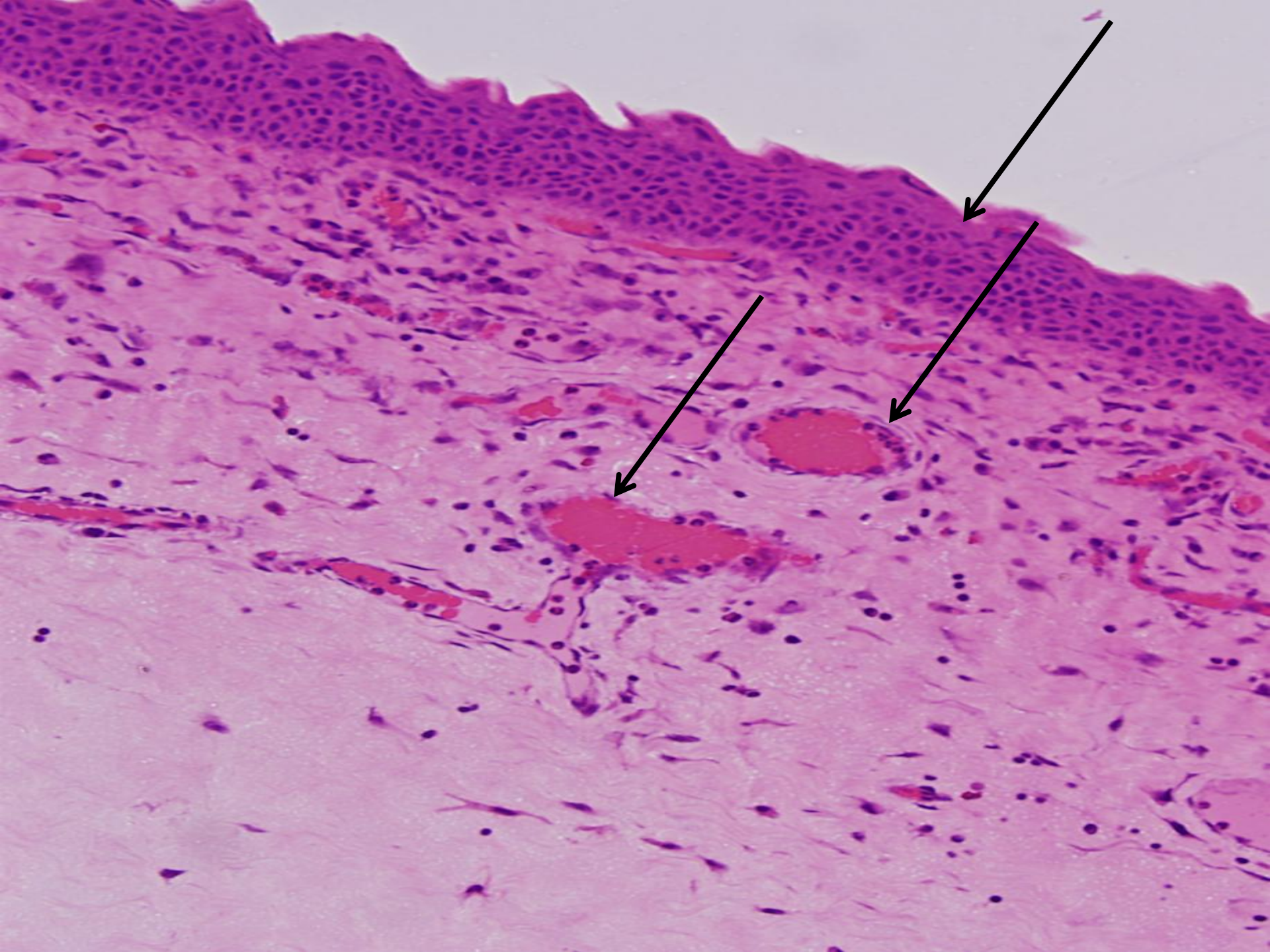
Pattern homogenous

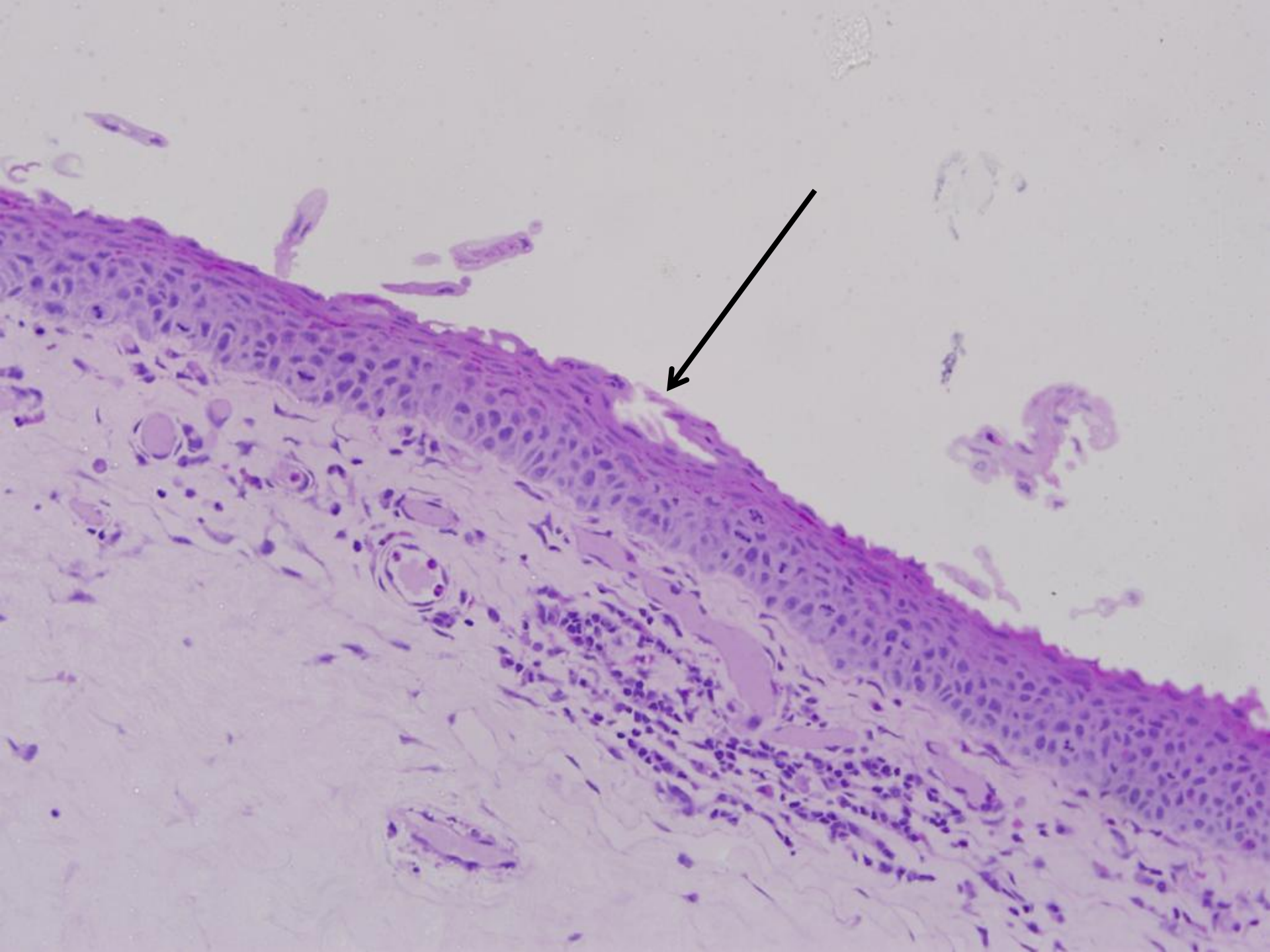


C1Q complexes: 8.1 (<4.4 normal)

C3D complexes: 18 (<8 normal)

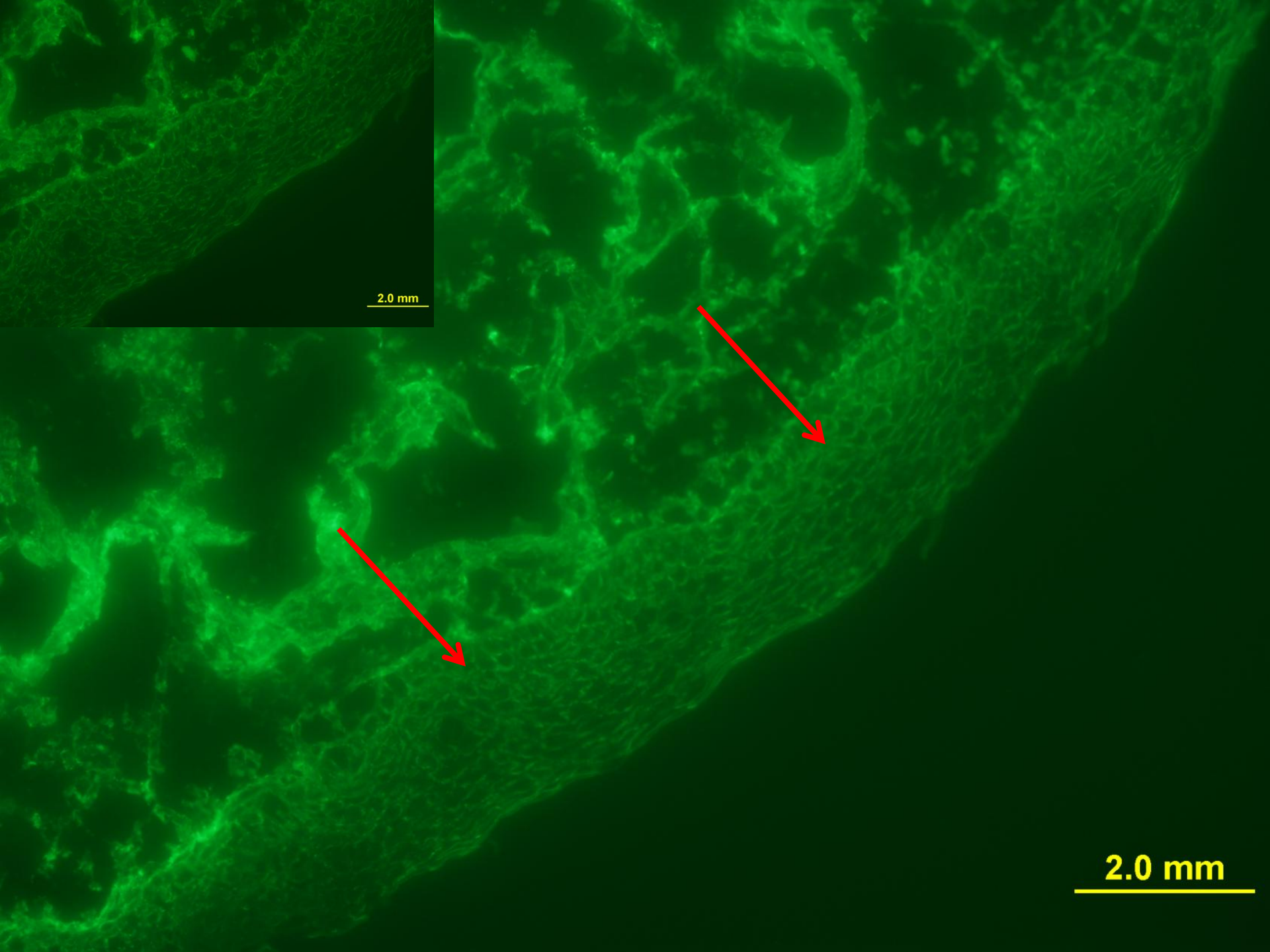









Direct IF staining of  
conjunctival biopsy with IgG

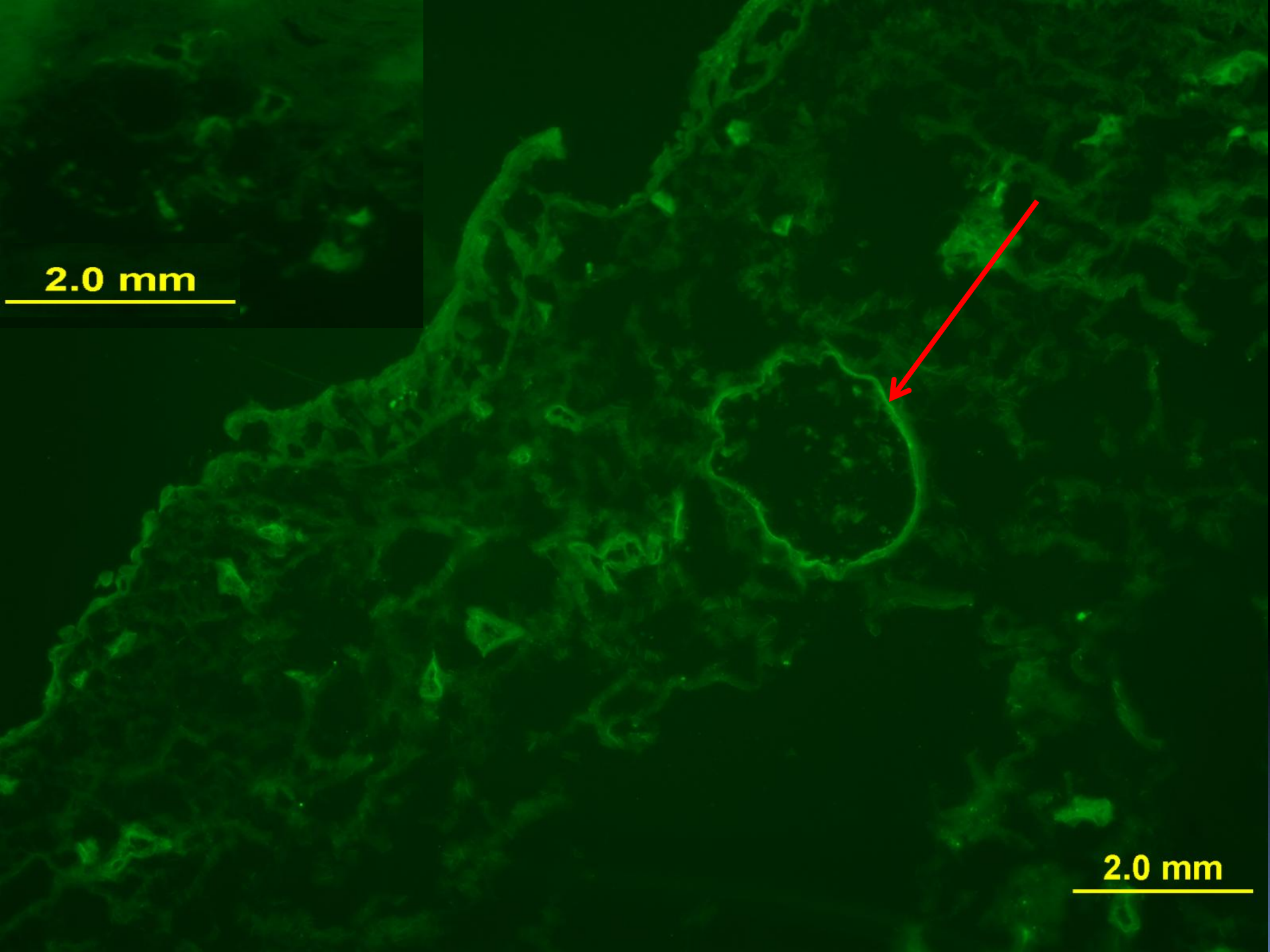


2.0 mm

2.0 mm




Direct IF staining of  
conjunctival biopsy with  
anti-HSV IgG



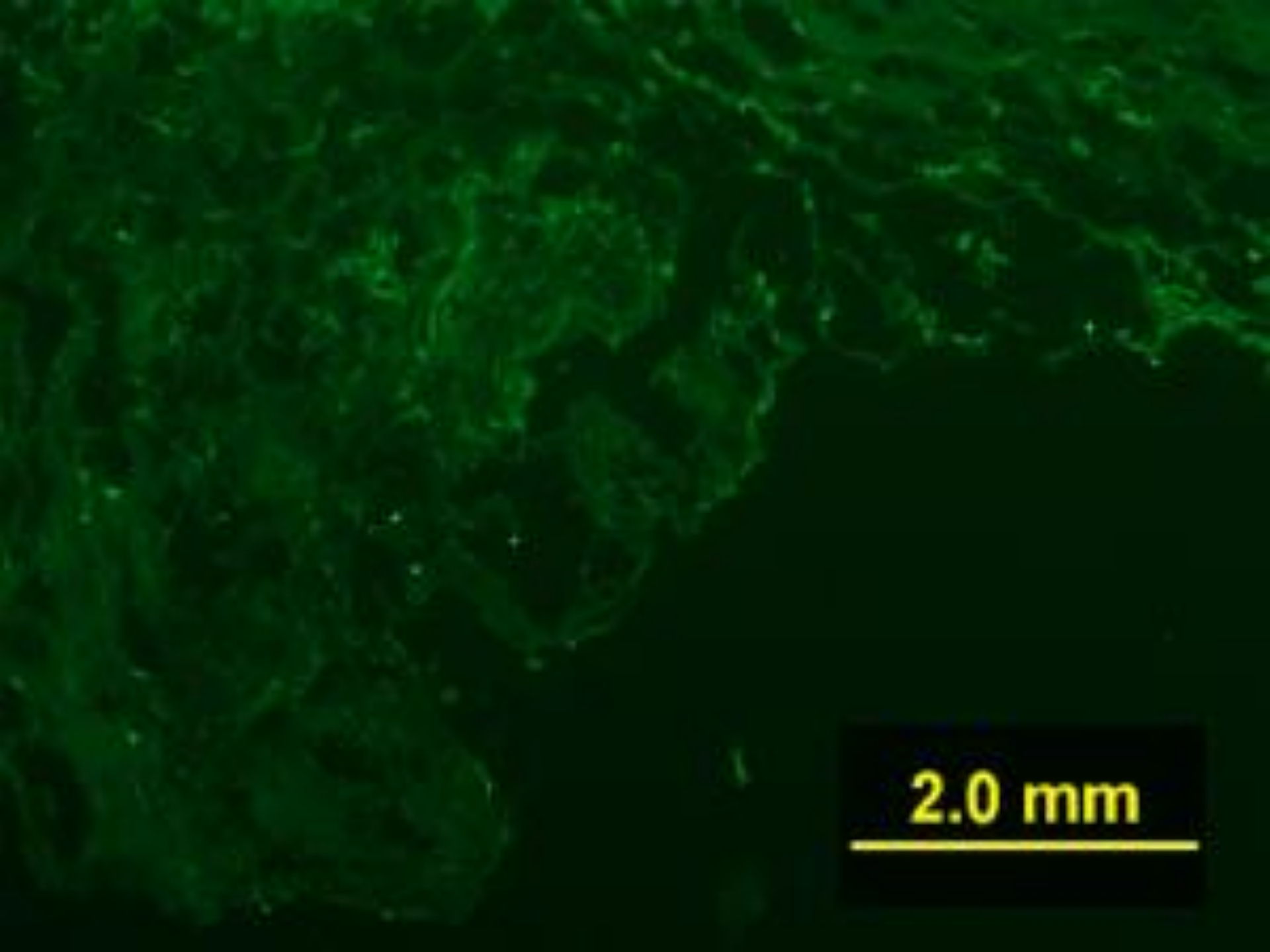
2.0 mm

2.0 mm





Direct IF staining of  
conjunctival biopsy with  
anti-VZV antibody (negative  
control)



2.0 mm



Diagnosis??


Ocular Pemphigus Vulgaris  
complicated by HSV





# Treatment

Acyclovir was replaced with Valacyclovir



Ocular inflammation has been quiet for the past 10 months while on therapy with IV-Ig infusions and valacyclovir, without topical steroids



**Thank You**