

Fungal Keratitis

Diagnosis and management

By Tatiana Romero Rangel

Case Presentation

CC: (7/14/97) foreign body sensation OD while mowing lawn.

HPI: 28y/o healthy man complained of foreign body sensation in his right eye while mowing the lawn. The patient consulted his local ophthalmologist.

Initial Course:

7/18-7/28: Rx: multiple Abx, no culture done

7/29 Corneal scraping done, and started:

Vancomycin (14mg/ml) q 15 min

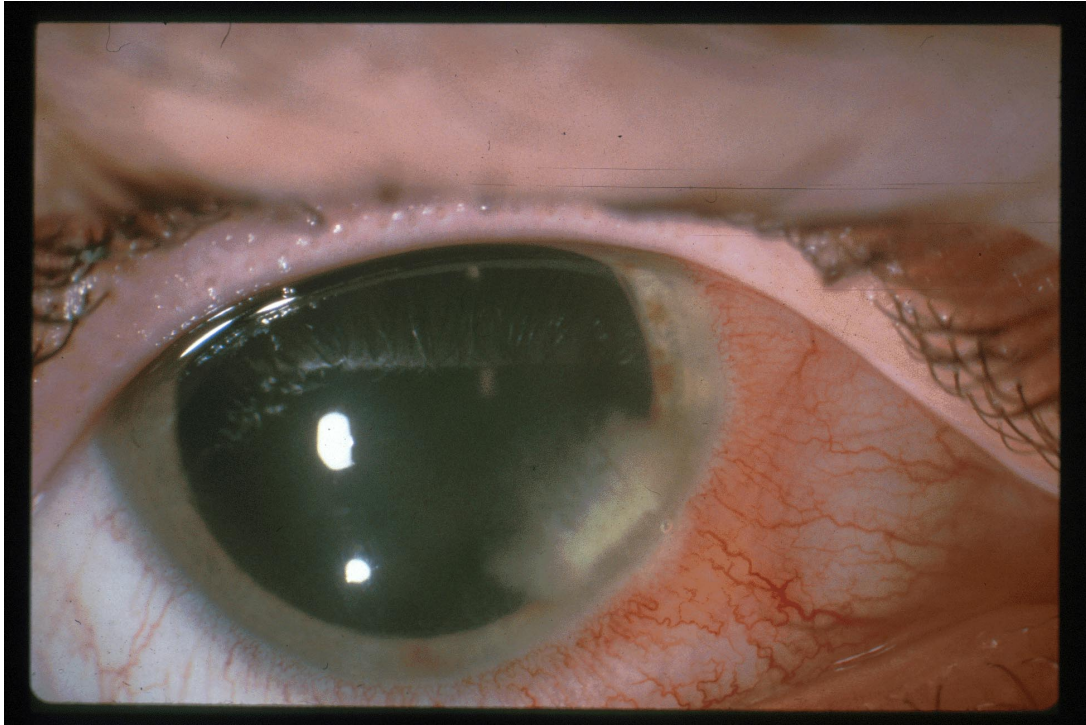
Tobramycin (13.6 mg/ml) q 15 min

7/30: Referred to MEEI

Examination:

VA: OD 20/40 OS 20/20

Corneal findings: stromal infiltrate adjacent to the limbus with feathery borders



Corneal sensation: OD 7/10 OS 10/10

Microbiology result from local hospital: Hyphae

Treatment at MEEI

- 1) Hospitalization
- 2) Amphotericin B 0.15% q 1 hr
- 3) Scopolamine 0.25% bid
- 4) Vancomycin q 3 hr
- 5) Ketoconazole 200 mg p.o bid

A Re-scraping was done. Culture on Calcofluor stain, blood, chocolate agar, and Saboraud Agar

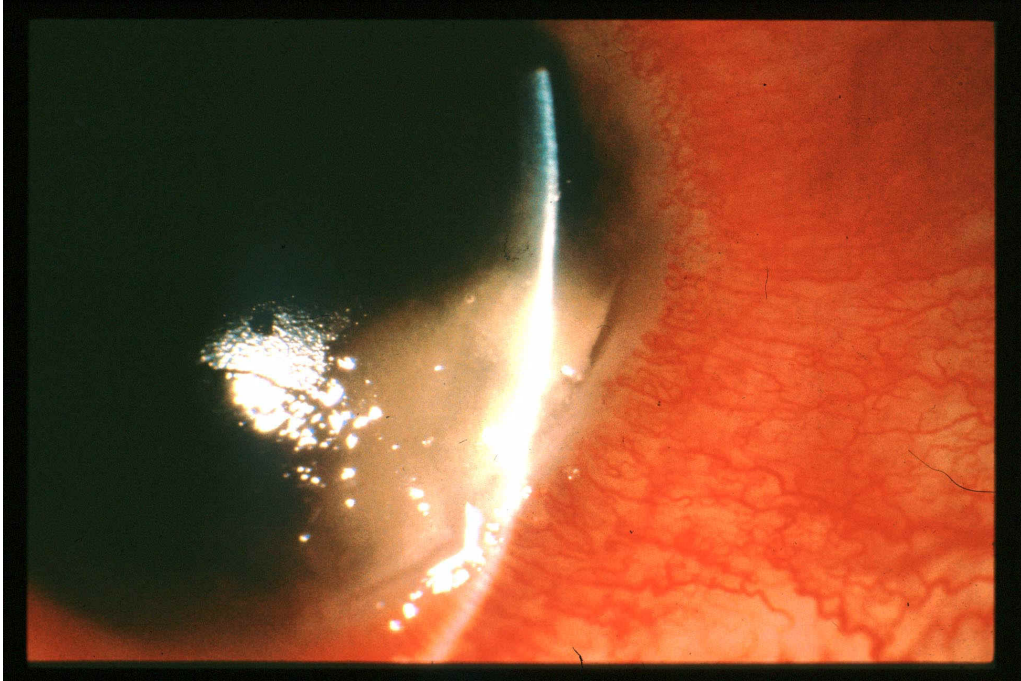
8/4/97: Culture grew *Aspergillus fumigatus*

Plan:

- 1) Discontinue Vancomycin
- 2) Change Ketoconazole to Itraconazole 200 mg bid
- 3) Add Fluconazole OD q1hr
- 4) Add Scopolamine OD qd

Clinical course:

In spite of this treatment, the cornea became thinner and an enlargement of the infiltrate was observed.

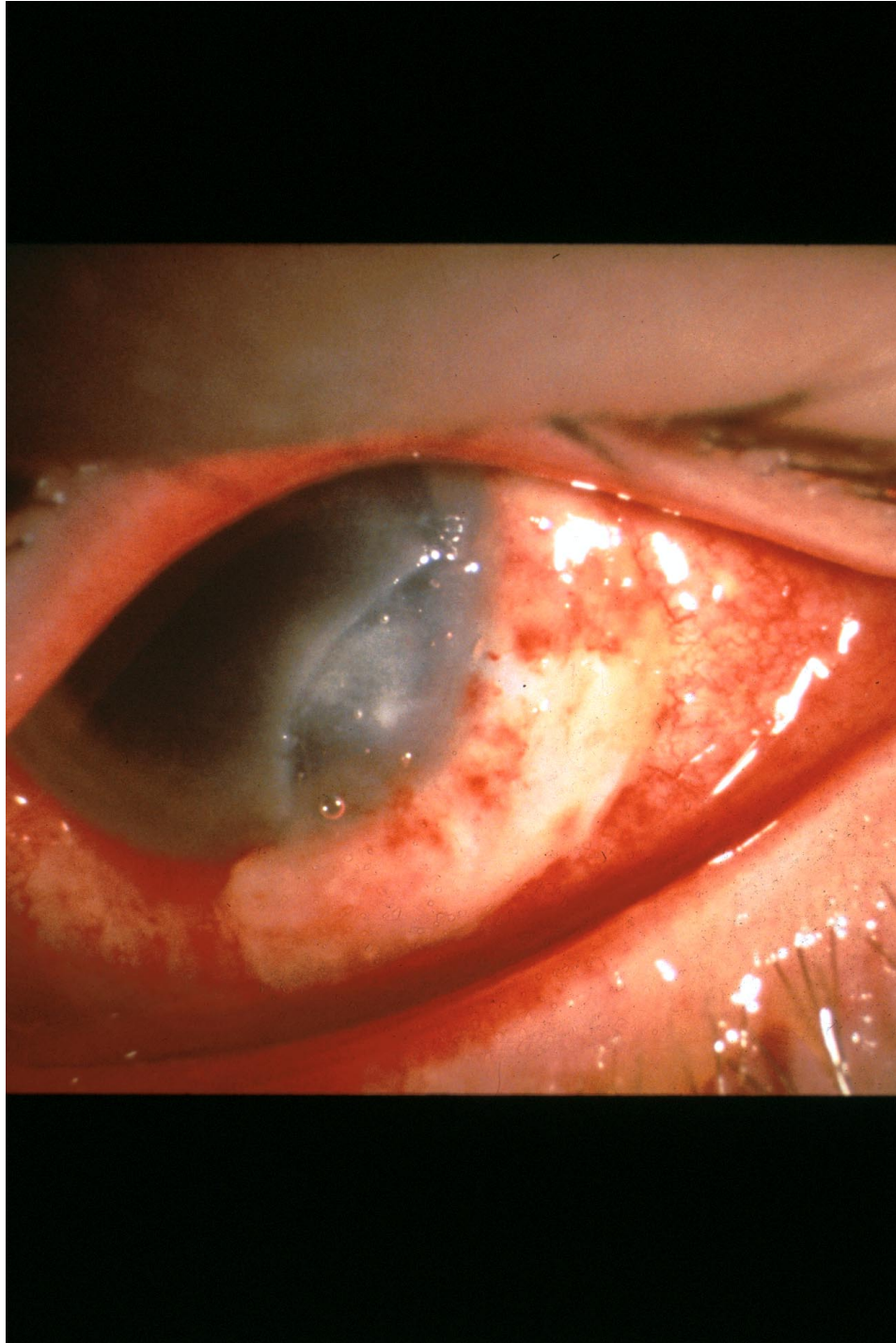


8/12/97 Patient underwent Keratectomy and partial sclerectomy

Corneal specimens grew abundant *A. fumigatus*.

Discontinued Fluconazole; started 5-fluocytosine.

8/12/97-8/20/97 Progressive corneal disease and increase scleral tenderness



Started Amphotericin IV

No clear improvement after over 200 mg of Amphotericin

An excisional biopsy was done (therapeutic PK)

No Steroids were used

8/20/97-9/4/97 Medical therapy consisted of:

- 1) Amphotericin IV (increased progressively)
- 2) Amphotericin OD 0.15% q1h
- 3) Fluocytosine OD q1h
- 4) Scopolamine OD bid

9/4/97 Patient was discharged from the hospital

VA OD: 20/200 (+ 6.00 lens) OS: 20/60
A/C 1+ cells, 1+ flare
IOP normal OU

Two weeks later, the patient was seen at the ER

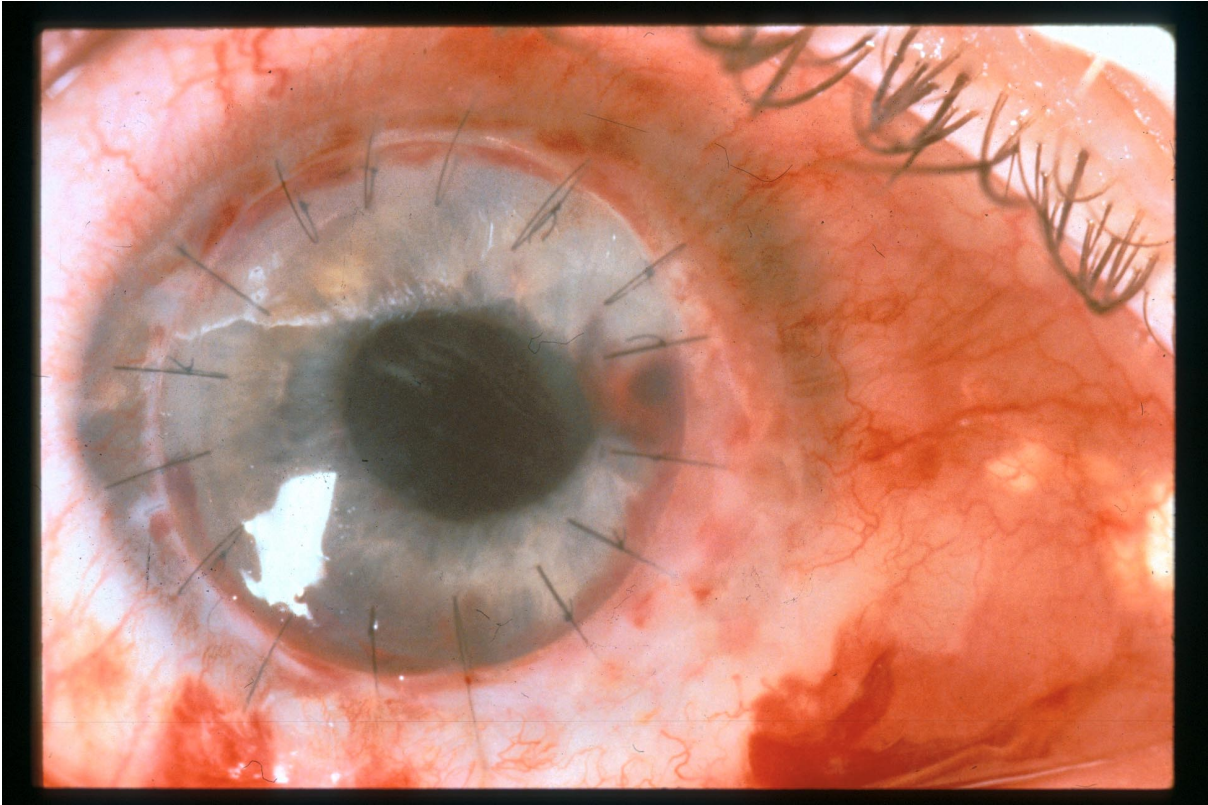
CC: Tearing , photophobia and decreased visual acuity

VA: OD: HM OS: 20/60
SLE: Diffuse corneal edema
Rejection line
Hazy view

Plan: 1) Itraconazole was increased

2) Steroids were not used

One month later, second PK was performed in an attempt to improve visual acuity.



Final VA: OD: 20/70

I. INTRODUCTION

Fungal Keratitis was first described by Leber in 1879. This entity is not a common cause of corneal infection, but it represents one of the major causes of infectious keratitis in tropical areas of the world. It is important to consider fungus as a possible cause of infectious keratitis because of the devastating ocular damage that it can produce if it is not diagnosed and treated promptly and effectively. Unfortunately, delayed diagnosis is common, primarily because of lack of suspicion and even if the diagnosis is made accurately; management remains a challenge due to the poor corneal penetration and limited commercial availability of antifungal drugs.

II. CLASSIFICATION

Seventy different fungi have been implicated as causing fungal keratitis. However, the two medically important groups responsible of corneal infection are yeast, and filamentous fungi (septate and non-septate). Yeast produce characteristic creamy, opaque, pasty colonies on the surface of culture media. *Candida* is the most representative pathogen in this group, affecting primarily corneas compromised by topical steroids, surface pathology, or both. A feathery, or powdery growth on the surface of culture media is produced by septate filamentary fungi, which are the most common cause of keratomycosis.

III. ETIOLOGY

Aspergillus is the most common cause of fungal keratitis worldwide. However, the epidemiology of keratomycosis is climate specific. In the Southern United States, *Fusarium* species are the

most common cause of keratomycosis, with an especially high incidence in Florida. In contrast, *Candida* and *Aspergillus* are the most common pathogens in the northern U.S.

IV. PATHOGENESIS AND RISK FACTORS

Fungus is not a common cause of microbial keratitis; fungi cannot penetrate the intact corneal epithelium and do not enter the cornea from episcleral limbal vessels. They need a penetrating injury or a previous epithelial defect in order to establish a "foot hold"; once within the cornea; they are able to proliferate. Organisms that infect pre-existent epithelial defects belong to the normal microflora of the conjunctiva and adnexa. The most common pathogen that invades a pre-existent defect is *Candida*; filamentous fungi are the principal causes of post-traumatic infection. Intrinsic virulence of fungi depends on the fungal substances produced and the host response generated.

Filamentous fungi proliferate within the corneal stroma without release of chemotactic substances, thereby delaying the host immune/inflammatory response. In contrast, *Candida albicans* produces phospholipase A and lysophospholipase on the surface of blastospores, facilitating the entrance to the tissue. *Fusarium solani*, which is a virulent fungus, is able (as are other filamentous fungi), to spread within the corneal stroma and penetrate Descemet's membrane.

Corneal trauma is the most frequent and major risk factor for keratomycosis. In fact, the physician should have a high level of suspicion if there is a patient with history of corneal trauma, particularly with plant or soil matter. The trauma that accompanies contact lens wear is miniscule; contact lenses are not a common risk factor of fungal keratitis. *Candida* is the principal cause of keratitis associated with therapeutic contact lenses; and filamentous fungi are the ones associated with refractive contact lens wear. Topical steroid use has definitively been implicated as a cause of increased incidence, development, and worsening of fungal keratitis. Other risk factors to consider are foreign body, corneal surgery, chronic keratitis, and immunosuppressive diseases.

Risk Factors for Filamentary Keratitis

- Young male
- Healthy
- No significant ocular disease
- Previous history of trauma (vegetable matter)
 - Agricultural occupations

Risk factors for *Candida* keratitis

- Older patient
- Pre-existing ocular disease

Exposure Keratopathy

Chronic keratitis

Chronic use of steroids

Immunosuppressive disease

V. CLINICAL

Diagnosis

The clinical diagnosis of fungal keratitis is based on analysis of risk factors and the characteristic corneal features. In terms of corneal infiltration the classic and specific findings are feathery margins, elevated edges, rough texture, gray-brown pigmentation, satellite lesions, hypopyon and endothelial plaque. However, advanced severe filamentous fungal and yeast keratitis are indistinguishable and resemble keratitis caused by virulent bacteria such as *Staphylococcus aureus* and *Pseudomonas aeruginosa*.

Although these highly characteristic signs may be present, it is of extreme importance to obtain material of the lesion by scraping or corneal biopsy before initiating treatment with antifungal therapy. Several unfortunate cases have been reported in which antifungal therapy was given before fungi were seen or isolated, with resultant misdiagnosis and progression of the process.

VI. LABORATORY

Diagnosis

The most important step in the initial management of suspected fungal keratitis is to obtain corneal material for directed smears and inoculation of media. Smears are used to obtain rapid information about the pathogen. Gram stain identifies yeast and Giemsa stain is useful in detecting fungal elements. However, if fluorescein microscopy is available, acridine orange and calcofluor white are the stains of choice. The primary isolation cultures for fungus are Saboraud and blood agar at room temperature. If the smear and cultures are negative at 48 to 72 hr in a patient with strong suspicion of having fungal infection, and the patient is not improving on the initial, broad-spectrum antibacterial therapy chosen, we recommend proceeding to corneal biopsy. If the corneal biopsy is still negative, the destructive corneal process is progressing, and hypopyon exists; anterior chamber paracentesis or excisional biopsy (keratoplasty) should be performed.

VII. ANTIFUNGAL THERAPY

It is important to emphasize that antifungal therapy should be limited to cases with positive fungal smears or cultures. Current available antifungal medications belong to the groups of polyenes, pyrimidine, imidazoles and triazoles that are summarized in the following table:

POLYENES

Amphotericin B 0.15% solution (from the IV preparation)
Natamycin 5% suspension

PYRIMIDINE

Flucytosine 1% aqueous solution 100- 150 mg/kg/day p.o

IMIDAZOLES

Clotrimazole 1% cream (vaginal preparation)
Ketoconazole 400 mg/day p.o
Miconazole 1% solution (vaginal preparation)

TRIAZOLES

Fluconazole 1% aqueous solution
200 mg/day p.o

Although, polyenes penetrate ocular tissue poorly, amphotericin B is the drug of choice for treatment of keratomycosis caused by *Candida*. In addition, it has efficacy against many filamentous fungi. Administration is every 30 minutes for the first 24 hours, every hour for the second 24 hours, then very slowly is tapered according to the clinical response. Natamycin is the only commercially available topical ophthalmic antifungal preparation. It is effective against filamentous fungi, particularly for infections caused by *Fusarium*. However, due to the poor ocular penetration it has been useful in the clinical practice primarily in cases with superficial corneal infection.

Flucytosine may be given with amphotericin B or miconazole; it is synergistic with these medications. Otherwise, if this is the only drug used in therapy for *Candida* infections, emergence of resistance rapidly develops. Therefore, Flucytosine should never be used alone.

Imidazoles and triazoles are synthetic chemical antifungal agents. High cornea levels of ketoconazole and fluconazole have been demonstrated in animal studies. Due to the excellent penetration in ocular tissue these medications given systemically are the preferred treatment for keratitis caused by filamentous fungi and yeast. Ketoconazole dose for adults is 200-400mg/day, which can be increased to 800 mg. However, because of the secondary effects careful increasing of the dose should be done. Gynecomastia, oligospermia and decreased libido have been reported in 5 to 15 % of patients who have been taking 400 mg/day for a long period. The potential role of itraconazole in therapy of keratomycosis is still unclear. However, it may also be a helpful adjunctive agent in fungal keratitis.

The promotion of fungal growth by corticosteroid treatment is well recognized. Therefore, steroids *should be avoided* in fungal keratitis.

Current treatment of keratomycosis is summarized in the next table:

Organism	First choice	Second choice
Yeast	•Flucytosine, 1% drops*	Miconazole 1% drops*

Filamentous	Amphotericin B, 0.15%	Clotrimazole, 1% cream
Superficial	drops*	Fluconazole, 200mg
Deep	•Fluocytosine, 150 mg/kg	p.o
	p.o	Amphotericin B, 0.15mg
	Natamycin, 5%	Drops*
	Suspension	Miconazole, 1% drops*
	Amphotericin B, 0.15%	Ketoconazole, 400mg
	Drops	p.o
	Rifampin	

***All drops administered hourly around the clock**

VIII. MODIFICATION OF THERAPY

Decisions about alternate therapy must be based on the biomicroscopic signs and tolerance of the topical medications. Improvement in clinical signs may be difficult to detect during the initial several days of effective antifungal therapy. However some of the biomicroscopic signs that may be helpful to evaluate efficacy are:

1. Blunting of the perimeters of the infiltrate
2. Reduction of the density of the suppuration
3. Reduction in cellular infiltrate and edema in the surrounding stroma
4. Reduction in A/C inflammation
5. Progressive re-epithelization
6. Loss of the feathery perimeter of the stromal inflammation

Successful antifungal therapy for keratomycosis requires frequent drug administration for prolonged periods. The minimal requirement for most cases of filamentous and cases where the posterior part of the stroma is affected is 12 weeks. Some corneal manifestations of toxicity are:

1. Protracted epithelial ulceration
2. Punctuate corneal epithelial erosion
3. Diffuse stromal haze

IX. SURGICAL THERAPY

Fungal keratitis is a surgical disease in most parts of the world because of the inability to obtain isolation of the fungus and the delayed initiating medical treatment.

1) *Debridment*: It is the simplest form of surgical intervention. The organisms and necrotizing material is removed and the penetration of antifungal medications is enhanced by the removal of

the epithelium, which is a barrier for the topical antifungals. Debridement should be performed every 24 to 48 hours

2)*Biopsy*: May be used for diagnostic or therapeutic treatment.

3)*Penetrating keratoplasty (PK)*: Should be performed sooner rather than later in keratomycosis cases not responding to aggressive antifungal therapy. If the infectious process progresses and fungus reach the limbus or sclera it will be too late for keratoplasty to rid the eye of viable fungus and the eye will be destroyed by the fungal infection.

X.

Summary

1. Fungal Keratitis should be kept in mind in the differential diagnosis of keratitis, especially if there is a risk factor; because the devastating ocular consequences that can occur if the diagnosis and treatment is not made promptly.
2. Antifungal therapy should be limited to cases with positive fungal smears or cultures.
3. Modify the initial therapy based on clinical response
4. Penetrating keratoplasty sooner rather than later
5. Steroids must be avoided.