

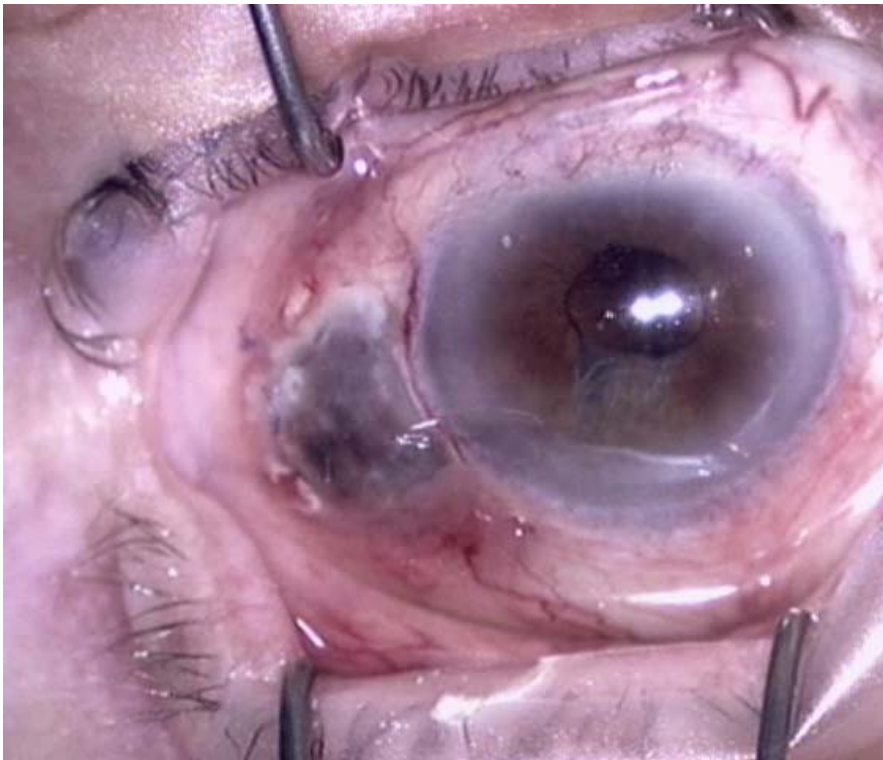## Case Presentation

David Hinkle MD and C Stephen Foster MD

An 81 year old woman presented with blurry vision and right eye photopsias three weeks following pars plana vitrectomy and explantation of a dislocated intraocular lens. She also complained of “boring pain” in the right eye for the previous five months which was not alleviated with acetaminophen. Past medical history was significant for hypertension, arrhythmia, and perforated peptic ulcer. A thorough review of systems was non-contributory.

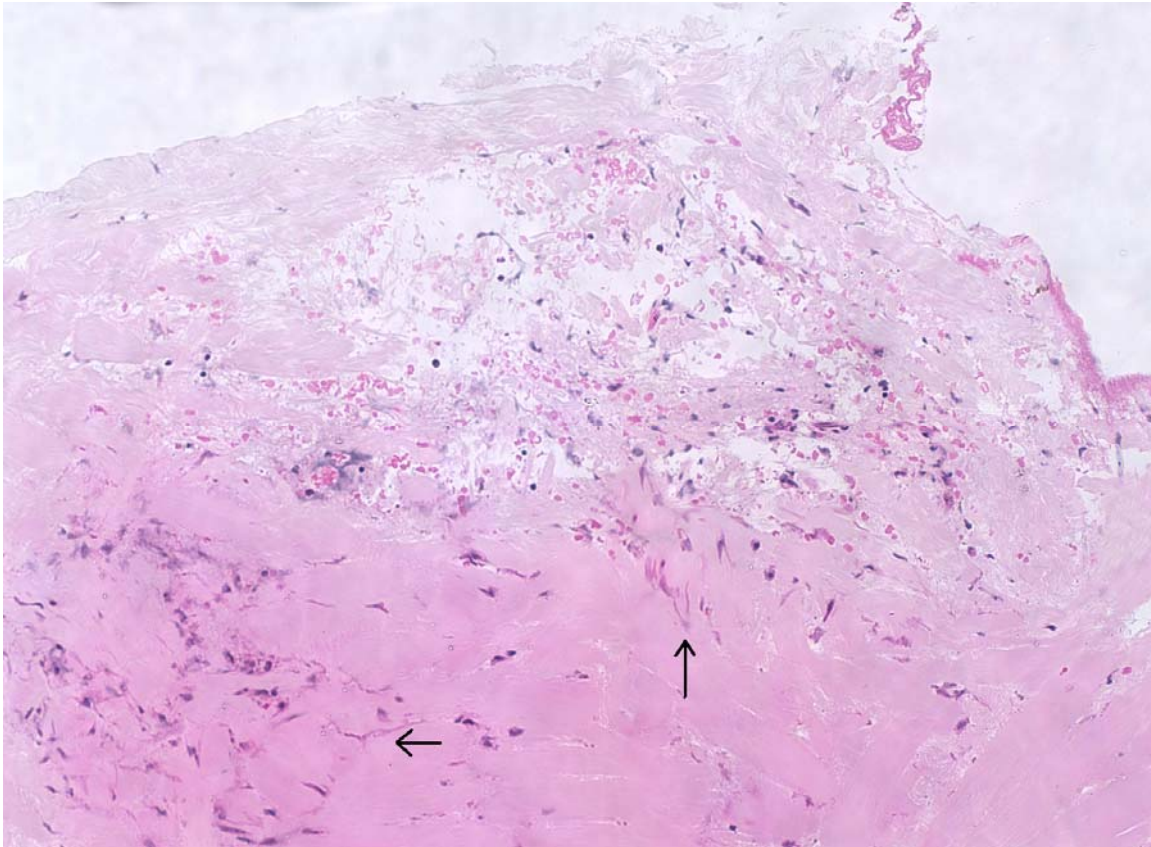
Visual acuity was counting fingers with improvement to 20/200 with pinhole occlusion. Right lower eyelid entropion was present. The globe was soft to palpation. A large area of scleral thinning with focal Seidel positivity was observed at the site of the inferior temporal infusion sclerostomy suture (Figure 1).

**Figure 1.** Preoperative photograph demonstrating large area of necrotizing scleritis.



A serologic examination for systemic causes of necrotizing scleritis was negative. The patient underwent scleral biopsy and patch grafting. Scleral biopsy cultures were negative; however, histopathologic examination disclosed branching filamentous fungi (Figure 2).

**Figure 2.** Light photomicrograph with hematoxylin and eosin stain of scleral tissue demonstrates numerous branching filamentous fungi (arrows).



Topical amphotericin B and systemic voriconazole therapy was instituted for 3 months. There has been no recurrence in the donor or host sclera.

### **Discussion**

Post-operative scleritis necessitates a meticulous pursuit for potentially lethal systemic autoimmune vasculitic diseases which may initially manifest following ocular surgery.

Microbial scleritis accounts for 5 to 60% of post-operative necrotizing scleritis in case reports in the ophthalmic literature. The most common pathogens include *Treponema pallidum*, *Mycobacterium tuberculosis*, *Mycobacterium leprae*, *Varicella-zoster virus*, *Acanthamoeba* species, and *Pseudomonas* species.<sup>1</sup> Risk factors include trauma, contaminated foreign bodies (i.e. sclera buckle), and prior exposure to mitomycin C or beta irradiation.

Fungal species associated with postoperative scleritis include *Aspergillus*, *Aureobasidium*, *Microsporidia*, *Rhizopus*, *Scedosporium*, and *Sporothrix*.<sup>2-7</sup> Antifungal

agents with good ocular penetration and/or broad spectrum of activity such as amphotericin B, fluconazole, and voriconazole should be instituted until culture results can direct therapy.<sup>8</sup> Eradication of the microbe is impaired due to the avascular nature of sclera and poor antibiotic penetration. Debridement and cryotherapy may be beneficial. The prognosis is frequently poor.

## References

1. Hemady R, Sainz de la Maza M, Raizman M, Foster CS. Six cases of scleritis associated with systemic infection. *Am J Ophthalmol.* 1992;114(1):55-62
2. Howell A et al. *Aspergillus flavus* scleritis: successful treatment with voriconazole and caspofungin. *Medical Mycol* 2005;43(7):651-5.
3. Gupta V, Chawla R, Sen S. *Aureobasidium pullulans* scleritis following keratoplasty: a case report. *Ophthalmic Surg Lasers.* 2001;32(6):481-2
4. Bernauer W, Allan BD, Dart JK. Successful management of *Aspergillus* scleritis by medical and surgical treatment. *Eye.* 1998;12:311-6.
5. Locher DH et al. Postoperative *Rhizopus* scleritis in a diabetic man. *JCRS* 1998;24(4):562-5.
6. Taravella MJ, Johnson DW, Petty JG, Keyeser RB, Foster CS, Lundberg BE. Infectious posterior scleritis caused by *Pseudallescheria boydii*. *Clinicopathologic findings.* *Ophthalmology.* 1997 ;104(8):1312-6.
7. Brunette I, Stulting RD. *Sporothrix schenckii* scleritis. *Am J Ophthalmol.* 1992;114(3):370-1.
8. Hariprasad SM, et al. Determination of vitreous, aqueous, and plasma concentration of orally administered voriconazole in humans. *Arch Ophthalmol.* 2004;122(1):42-7.