

# NECROTIZING SCLERITIS: DIAGNOSIS AND THERAPY

Esen Karamursel Akpek, M.D.

## ABSTRACT

*PURPOSE/METHODS:* Necrotizing scleritis is the most severe and destructive form of scleritis, sometimes leading to loss of the eye from multiple complications, severe pain, or occasionally perforation of the globe. Here we discuss the evaluation and management of a necrotizing scleritis case in a patient with rheumatoid arthritis who presented with perforation of the globe. *CONCLUSION:* Progressive inflammatory destruction of the sclera or cornea may occur in association with systemic disorders in which vasculitis is a feature. The successful management of the ocular destruction in such instances will always require correct treatment of the underlying systemic disorder and also some form of ocular surgical management.

## INTRODUCTION

Scleritis is a severe, destructive inflammatory disease affecting the eye wall. In Watson's series, 46% of the patients had an identifiable systemic disease (1). Rheumatoid arthritis is by far the most common systemic condition associated with scleritis (2). The ongoing active vasculitic process if not treated properly, may lead to death due to the systemic complications in a patient with autoimmune disease.

## CASE REPORT

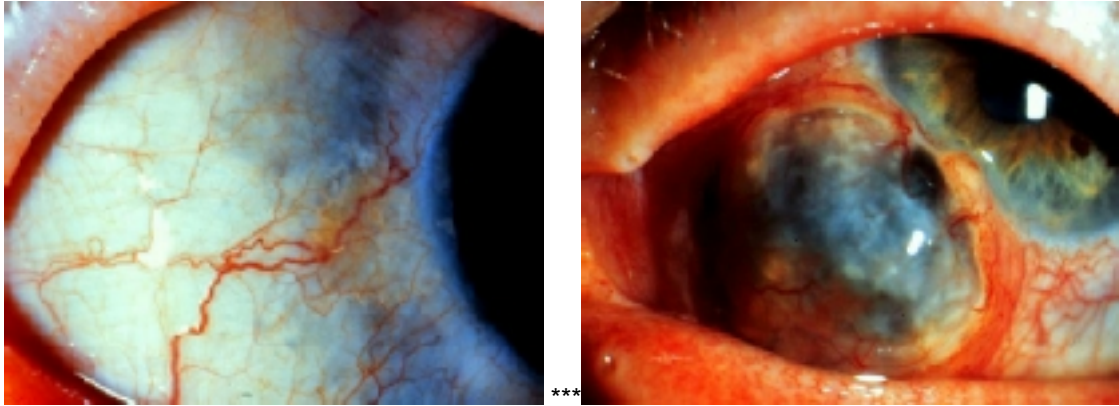
A 57 year old white female was referred as an emergency, on July 6, 1994 by her rheumatologist with the symptoms of pain, decreased visual acuity and photophobia, left eye.

The patient had a history of OS redness and pain beginning 1 year ago, treated with local steroids by her local ophthalmologist. In May, 1994 she was seen by a retina specialist because of the progressing scleral melting.

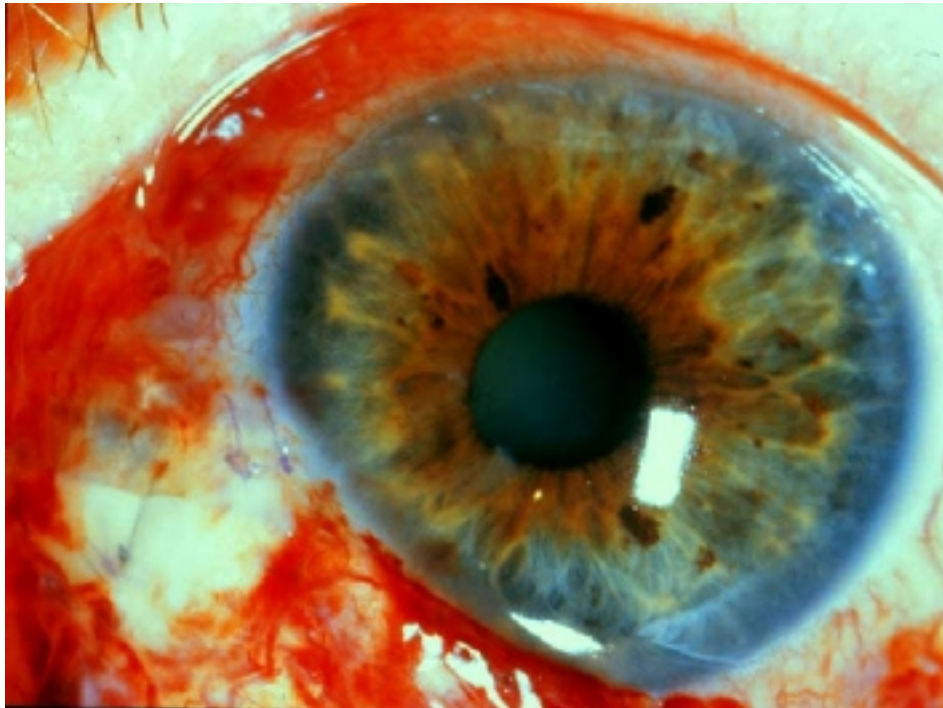
Her mother and aunt had rheumatoid arthritis. Past medical history revealed rheumatoid arthritis of 10 years duration, treated with Naprosyn, gold and Imuran. Diverticulosis, osteoporosis, and previous bilateral hip replacement, appendectomy and cervical polypectomy were additional historical features.

At the time of presentation the patient was on methotrexate 12.5 mg/week subcutaneously, prednisone 7.5 mg qd, calciferol and ibuprofen 400 mg every 4 hours.

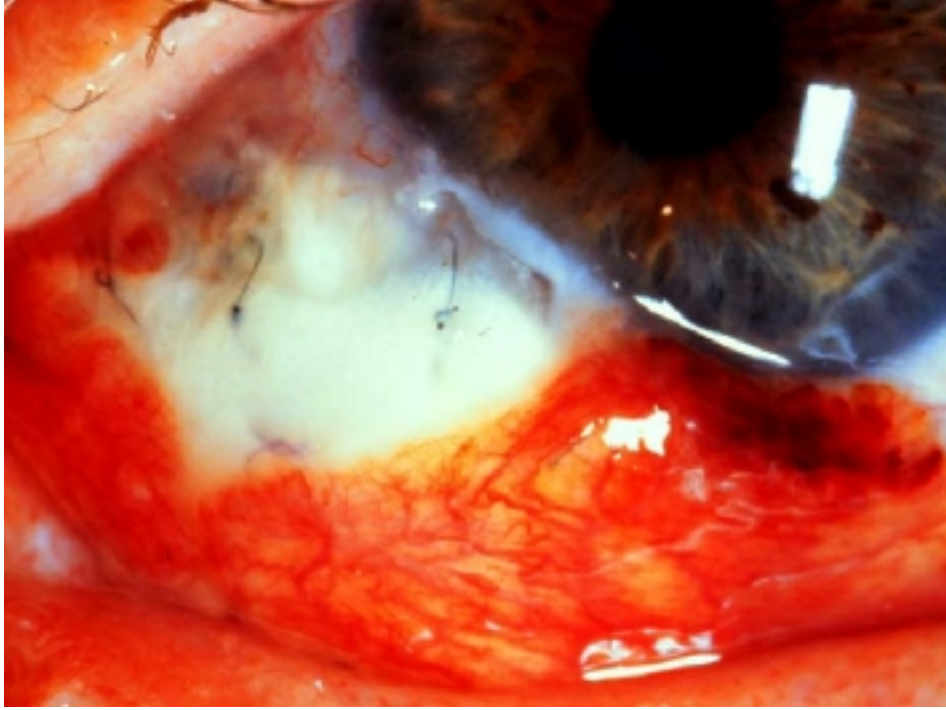
Examination revealed vision of 20/20 OD and 20/200 OS. Intraocular pressures were 14 and 10 mmHg right and left eye respectively. Slit lamp examination of the right eye revealed a bluish discoloration of the sclera perilimbally and the left eye had a large area of scleral thinning and uveal prolapse inferonasally and a frank perforation on the limbus at 7 o'clock.



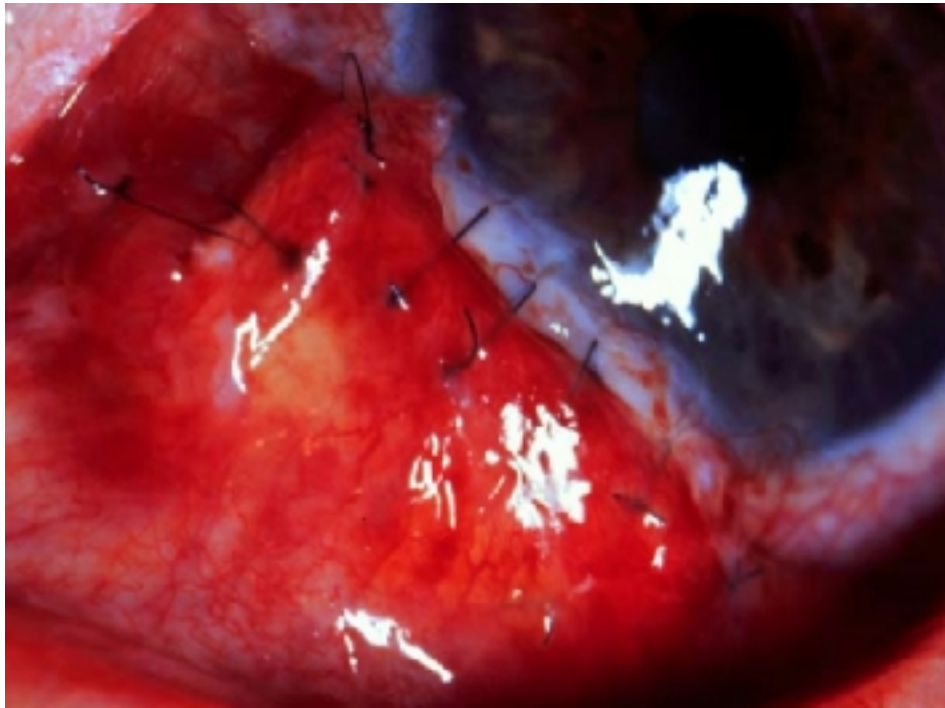
Active necrotizing scleritis with perforation associated with rheumatoid arthritis was diagnosed, and the patient was hospitalized as an emergency to receive a scleral graft. On July 8, 1994 the first scleral graft was performed.



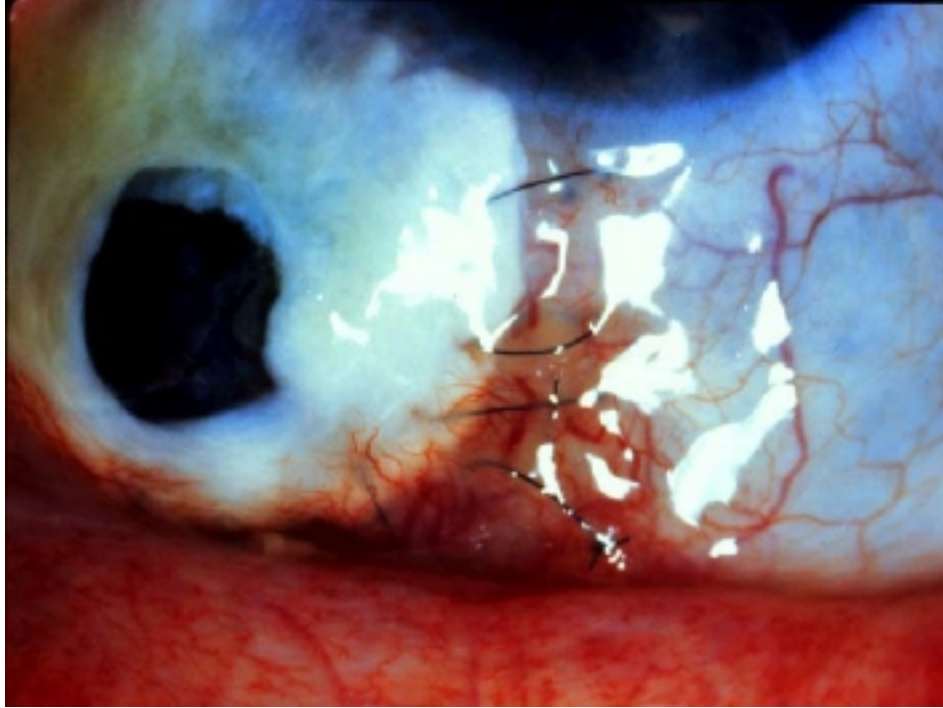
Methotrexate was discontinued and IV Cytoxan 1200 mg was administered. The patient did well on oral Cytoxan 150 mg and prednisone 20 mg after discharge until August 1994 when she presented with a melting scleral graft.



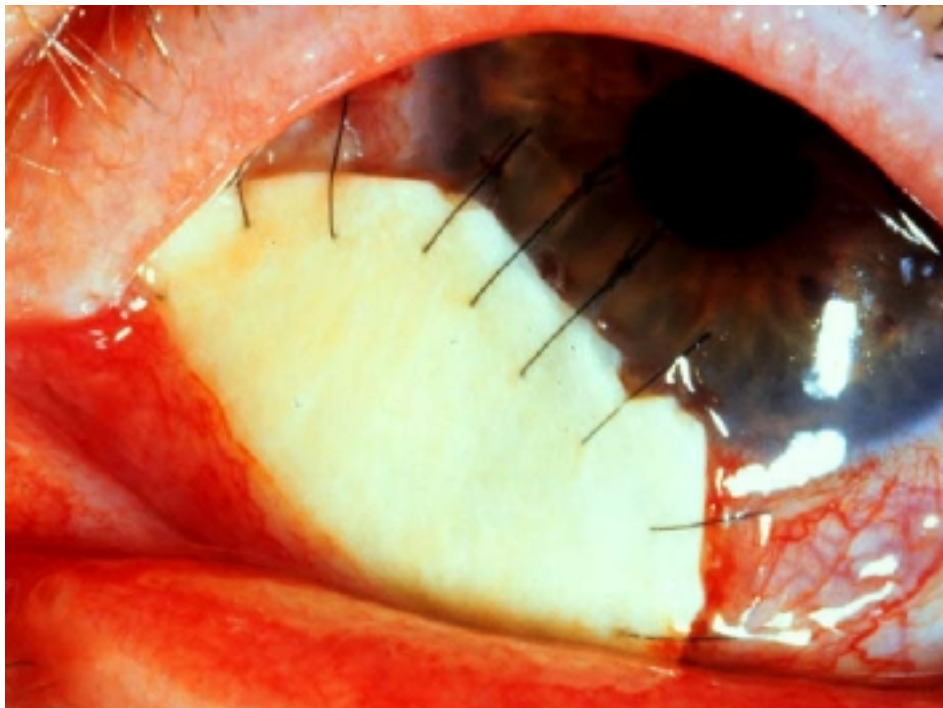
She was scheduled for a repeat graft and put on IV Cytosan due to nausea intolerance to oral Cytosan. On August 25, 1994 the second scleral graft was performed.



In October 1994 the graft melted again.



The IV Cytoxan dose was increased to 1600 mg, and prednisone to 15 mg and the third scleral graft was performed on October 3, 1994.



In March, 1995 the graft again melted, despite therapy with 1350 mg IV Cytoxan, every 3 weeks and 10 mg prednisone per day. On March 15, 1995 the fourth scleral graft was performed. IV Cytoxan 1200 mg every 3 weeks, and 10 mg of oral prednisone were continued. The graft survived, but her vision started to decrease due to the bilaterally developing cataracts. On

September 20, 1995 patient presented with a decrease in her vision. Examination disclosed visual acuities of 20/40 OD and 20/200 OS, 2+ NS, OD and 3+ NS, 2+ PSC, OS. The scleral graft was secure and totally conjunctivalized. The patient was scheduled for cataract extraction and intraocular lens implantation, OS. On October 16, 1995 the right eye and on December 11, 1995 the left eye were operated without any complications and the posterior chamber intraocular lenses were placed successfully. Meanwhile she was still on IV Cytoxan and low dose prednisone. In January, after having completed one year of chemotherapy, the Cytoxan was discontinued.

As of her last follow-up, the patient's scleral graft is conjunctivalized and secure, there was no evidence of scleral inflammation, and the visual acuities were 20/20 OD, and 20/40 OS.

## **DISCUSSION**

Scleritis is a severe inflammatory condition that is characterized by edema and inflammatory cell infiltration of the sclera. The most common presenting symptoms are the pain and redness. It is most common in the fourth to sixth decades, with a peak incidence in the fifth decade (2). In 40 % of the cases it is bilateral (3).

## **PATHOGENESIS**

The presence of microangiopathy in most of the scleritis specimens suggests an underlying immune complex reaction (Type III hypersensitivity reaction ) in which the vascular injury is the result of antigen-antibody conjugation within and outside of the vessel wall, with subsequent activation of complement, attraction of neutrophils and fibrinoid necrosis of vessels and surrounding tissue. The antigen is usually the aberrant expression of the HLA-DR on scleral fibroblasts, induced by interferon gamma (4).

## **CLASSIFICATION**

Scleritis has been classified depending on the site of pathology and severity of inflammation (5).

- Anterior:
  - diffuse
  - nodular
  - necrotizing
    - with inflammation
    - without inflammation
- Posterior

The inflammation of diffuse scleritis is generalized, involving some area of the whole anterior segment. On slit lamp examination, the superficial and deep episcleral plexes are not only congested but also distorted and tortuous, losing the normal radial pattern. When the inflammation disappears, the sclera may show a bluish color due to the rearrangement of the collagen fibers. This increased translucency is not always accompanied by scleral thinning.

In the nodular type of scleritis, the inflammation is localized to one or more scleral nodules which are immobile and firm to the touch. Slit lamp examination reveals the congestion and tortuosity of the superficial and deep episcleral plexes overlying the nodule. These nodules are usually localized in the interpalpebral region close to the limbus.

Necrotizing scleritis is the most severe and destructive form of scleritis, sometimes leading to loss of the eye from multiple complications, severe pain, or perforation of the globe. The pain, always



present without adequate medication, may be so intense and provoked by minimal touch to the scalp that it may sometimes seem out of proportion to the ocular findings.

On slit lamp examination one can see the white avascular areas surrounded by swelling of the sclera and acute congestion of the abnormal episcleral vessels. The progression around the globe, leading to loss of tissue, may appear within a few weeks if the inflammation is severe.

If the defect is small, replacement by thin fibrous tissue may occur. But if the defect is large, scleral grafting should be performed and must always be accompanied with systemic immunosuppressive therapy.

Scleromalacia perforans is characterized by the appearance of yellow or grayish anterior scleral nodules that gradually develop a necrotic slough or sequestrum eventually separating from the underlying sclera, leaving the choroid bare or covered only by a thin layer of conjunctiva.

Slit lamp examination reveals a reduction in the size and the number of the vessels in episclera surrounding the sequestrum, giving a porcelain like appearance.

The presenting signs and symptoms in posterior scleritis are usually pain, unless it is pure posterior scleritis, redness, chemosis, lid edema, lid retraction, proptosis and decreased visual acuity.

Fundus examination reveals choroidal folds, subretinal mass, disc edema, macular edema, annular ciliochoroidal detachment and serous retinal detachment.

## **DIFFERENTIAL DIAGNOSIS**

Both diffuse and nodular episcleritis must be differentiated from scleritis. The patient with episcleritis never complains about pain. The eye appears salmon pink to fiery red but never bluish, and the sclera is never edematous. Since the enlarged vessels are in the superficial episcleral plexus, they constrict in the presence of 10 % phenylephrine.

In scleritis the patient always has pain, the color is violaceous and on slit lamp examination, due to the scleral edema, the light beam is displaced forward.

Scleral hyaline plaque develops in elderly people between cornea and insertion of the lateral and medial rectus muscles, and can simulate necrotizing scleritis without inflammation. But unlike scleromalacia perforans the overlying conjunctiva is healthy (6).

In paralimbal scleromalacia the degenerative process occurs at the corneoscleral limbus. It is characterized by a slowly progressive, non-inflammatory, painless scleral thinning that leads to a spontaneous small perforation with iris prolapse. The appearance resembles the filtering bleb of an Elliot trephining operation (7).

In Mooren's ulcer there is no scleral involvement and no systemic disease association. Anterior segment angiography reveals that the normal radial pattern of vasculature is preserved, unlike scleritis (8).

Since posterior scleritis can present with proptosis, lid swelling, limitation of ocular movements, one must think about orbital tumor, inflammatory pseudotumor or thyroid ophthalmopathy in the differential diagnosis.

With regard to the subretinal mass finding, choroidal melanoma, metastatic uveal carcinoma, or choroidal hemangioma must be excluded.

Sometimes posterior scleritis can present as serous detachment of choroid, ciliary body or retina. In these cases, it must be differentiated from uveal effusion syndrome, Vogt-Koyanagi-Harada disease or central serous retinopathy (9).

## **DIAGNOSTIC TESTS**

To be able to detect the underlying disease, for proper treatment and assessment of prognosis, some diagnostic work-up is always indicated in patients with scleritis.

Rheumatoid Factor: autoantibodies specific for epitopes in the Fc fragment of IgG. They can be IgG, IgM, IgA type. Almost 80 % of the patients with rheumatoid arthritis are RF positive(10).

ANAs actually compose a family of autoantibodies directed against the components of the cell nucleus. They are important indicators for SLE and related syndromes (11).

ANCA is the IgG autoantibody directed against a cytoplasmic antigen of human neutrophils, mostly related to Wegener's granulomatosis but also microscopic polyarteritis nodosa(12).

In patients with autoimmune disorders, circulating immune complexes can persist in the circulation longer than in normal individuals (13). C1q binding is particularly sensitive for circulating immune complexes containing IgM. Therefore high levels are usually observed in rheumatoid arthritis (14). Raji cell binding assay is particularly sensitive to IgG containing immune complexes (15).

Any disease that gives rise to circulating immune complexes, can lead to hypocomplementemia, and so depressed levels of C3 or C4. Chest, sinus, sacroiliac, limb joint x-rays can help in the diagnosis of arthritis, Wegener's disease, tuberculosis, atopy...

The anterior segment angiography reveals early leakage into the extravascular space, venular obstruction, especially in necrotizing type arteriolar beading, non-perfused areas, increased transit time and distortion of normal radial pattern of episcleral vessels (8).

Fundus fluorescein angiography reveals circumscribed fundus mass, choroidal folds, retinal striae, disc edema, annular choroidal detachment, exudative macular detachment, cystoid macular edema and localized peripheral retinal detachment (16).

B scan USG is by far the most useful investigation in suspected posterior scleritis cases. Increased thickness of the posterior coats of the globe, separation of the posterior surface of the sclera from the episclera, presence or absence of retinal or choroidal detachments or swelling of the disc are the common findings (16).

CT and MRI scans are especially important in differential diagnosis of posterior scleritis or the diagnosis of the underlying disease.

The major finding in biopsy of scleritis is the inflammatory microangiopathy which shows the neutrophilic infiltration in and around the vessel walls of capillaries and post capillary venules(4).

## **SYSTEMIC ASSOCIATIONS**

Rheumatoid arthritis is by far the most common systemic condition associated with scleritis. The reported incidence of rheumatoid arthritis in patients with scleritis is 10 to 33 % (1,17,18). The diffuse anterior scleritis is the most frequent type, however cases of scleromalacia perforans in which a systemic diagnosis can be ascribed are almost exclusively due to rheumatoid arthritis. The other associated diseases are Wegener's granulomatosis, SLE, JRA, PAN, Relapsing Polychondritis, psoriasis, gout, atopy, rosacea, TB, syphilis, HSV, HZV.

## **COMPLICATIONS**

If not treated properly, scleritis may lead to profound complications.

Keratopathy: There are 3 types of keratopathies associated with scleritis; peripheral corneal thinning, stromal keratitis and peripheral ulcerative keratitis.

Peripheral corneal thinning is the most benign form of corneal involvement. Circumferential thinning with a well demarcated central edge without lipid deposition and minimal vascularization resembles the appearance of an eye wearing a hard contact lens and called  $\frac{3}{4}$  contact lens cornea  $\frac{3}{4}$  (19).

Stromal keratitis is the extension of the inflammation into the cornea. It can lead to sclerocornea (1).

PUK is the most severe form of corneal involvement in scleritis. It is usually associated with necrotizing scleritis and if not treated may lead to spontaneous perforation (20).

The presence of uveitis and glaucoma accompanying scleritis should be considered as grave signs. Because they indicate not only an extension of the inflammation to intraocular structures, but also the presence of complications that may cause progressive visual loss.

Cataract surgery should be attempted in the absence of active inflammation; corneal incision is preferred.

## **TREATMENT**

Treatment is based on the type of scleritis, severity of the inflammation and underlying systemic disease (9).

### *MEDICAL TREATMENT*

In patients with simple diffuse or nodular scleritis systemic non-steroidal antiinflammatory drug therapy is almost invariably effective unless the underlying disease is Wegener's granulomatosis, polyarteritis nodosa or relapsing polychondritis. Generally patients require a minimum of one year before attempting to taper and discontinue the medicine. Diflunisal ( 500 mg q 12h ) and naproxen sodium (500 mg q12h) are the two most effective choices.

For unresponsive cases and posterior scleritis, the mainstay of treatment is systemic steroids in a dose of 1 mg/kg/day. As soon as the patient responds, the dose should be tapered once 20 mg/day is reached, alternate day therapy can be started. Topical steroids can be applied for symptom relief.

Immunosuppressive therapy is mandatory for definitively diagnosed systemic vasculitic disease and/or progressive destructive ocular lesions. If the necrotizing scleritis is not severe, not rapidly progressing, the first choice of therapy is methotrexate 7.5 mg once a week as a starting dose,



with appropriate monitoring. If the disease is bilateral, not severe but rapidly progressive, or if the patient has not responded to methotrexate generally 2 mg/kg/day azathioprine is used. Cyclosporin 5 mg/kg/day can be used as an alternative.

If the patient fails to respond to these medications, or the patient has severe necrotizing scleritis the drug of choice is cyclophosphamide at a dose of 2 mg/kg/day with high fluid intake and close monitoring.

### *SURGICAL TREATMENT*

Extreme corneal thinning or perforation requires reinforcement. Donor sclera, fascia lata, periosteum or artificial materials can be used. To maintain its integrity the material must be covered by conjunctiva.

Extreme corneal marginal ulceration or keratolysis may require corneal grafting, usually as a lamellar patch graft.

### **REFERENCES**

1. Watson PG, Hayreh SS. Scleritis and episcleritis. *Br J Ophthalmol* 1976; 60:163-191
2. Watson PG. Diseases of sclera and episclera. In Tasman W, Jaeger EA (Eds): *Duane's Clinical Ophthalmology*, rev ed. Lippincott, Philadelphia, 1992, pp1-43
3. McCluskey, Wakefield D. Current concepts in the management of scleritis. *Australian and New Zealand Journal of Ophthalmology* 1988; 16:169-176
4. Fong LP, Sainz de la Maza M, Rice B, Kupferman AE, Foster CS. Immunopathology of scleritis. *Ophthalmology* 1991; 98: 472-479
5. Watson PG. The nature and treatment of scleral inflammation. *Trans Ophthal Soc UK* 1982; 102:257-281
6. Francois J. Scleromalacia perforans, arthritis deformans and pemphigus. *Trans Ophthalmol Soc UK* 1951; 71: 61
7. Sorensen TB. Paralimbal scleromalacia. *Acta Ophthalmol* 1975; 53: 901
8. Watson PG, Ortiz JM. *Color Atlas of Scleritis*. Mosby-Wolfe, 1995 pp 117-120
9. Foster CS, Sainz de la Maza M. *The Sclera*. Springer-Verlag, New York 1994, pp120-124
10. Carson DA. Rheumatoid factor. In Kelley WN, Harris ED Jr, Ruddy S, Sledge CB (Eds) *Textbook of rheumatology*, 3rd ed. WB. Saunders, Philadelphia, 1989, pp 664-679
11. Reichlin M. Antinuclear antibodies. In Kelley WN, Harris ED Jr, Ruddy S, Sledge CB (Eds). *Textbook of Rheumatology*, 3rd ed. WB. Saunders, Philadelphia, 1989, pp 690-706
12. Savage CS, Winearls CG, Jones S, et all. Prospective study of radioimmunoassay for antibodies against neutrophil cytoplasm in diagnosis of systemic vasculitis. *Lancet* 1987, 1: 1389
13. Nydegger VE, Kazatchkine MD, Lambert PH. Immune complexes. In Fougereau M, Dausset J (Eds). *Progress in immunology IV*. Academic Press, New York 1980
14. Zubler RH, Large G, Lambert PH, Miescher PA. Detection of immune complexes in untreated sera by a modified <sup>125</sup>I C1q binding test. Effect of heating on the binding of C1q by immune complexes application of the test to systemic lupus erythematosus. *J Immunol* 1976; 116:232
15. Theofilopoulos AN, Wilson CB, Dixan FJ. The Raji cell radioimmune assay for detecting immune complexes in human sera. *J Clin Invest* 1976, 57:169
16. Benson WE. Posterior scleritis. *Surv Ophthalmol* 1988, 32:297-316
17. Mc Gavin DDM, Williamson J, Forrester JV, Foulds WS, Bouchanan WN, Dick WC, Lee P, Mac Sween RN, Whaley. Episcleritis and scleritis: a study of their clinical manifestations and association with rheumatoid arthritis. *Br J Ophthalmol* 1976; 60:192
18. Lyne AJ, Pitkeathley DA. Episcleritis and scleritis. *Arch Ophthalmol* 1968, 80:171
19. Lyne AJ. "Contact lens cornea" in rheumatoid arthritis. *Br J Ophthalmol* 1970; 54:410

20. Sainz de la Maza M, Foster CS. The diagnosis and treatment of peripheral ulcerative keratitis. Semin Ophthalmol 195; 92:1436

## NECROTIZING SCLERITIS QUESTIONS

21. **Esen Karamursel Akpek, M.D.**

22. 1. What percentage of scleritis cases is associated with an underlying disease?  
23. a. 27 %  
b. 30 %  
c. 47 %  
d. 60 %  
e. 75 %
24. 2. What is the most common systemic disease associated with scleritis?  
25. a. Rheumatoid Arthritis  
b. Wegener's Granulomatosis  
c. Relapsing Polychondritis  
d. Inflammatory Bowel Disease  
e. Systemic Lupus Erythematosus
26. 3. Scleromalacia perforans is almost always associated with:  
27. a. Rheumatoid Arthritis  
b. Wegener's Granulomatosis  
c. Relapsing Polychondritis  
d. Inflammatory Bowel Disease  
e. Systemic Lupus Erythematosus
28. 4. What is the most useful investigation in the diagnosis of posterior scleritis?  
29. a. Orbital X-ray  
b. MRI  
c. A-scan USG  
d. B- scan USG  
e. CT Scan
30. 5. What is the most serious complication of scleritis?  
31. a. Peripheral corneal thinning  
b. Stromal thinning  
c. Peripheral ulcerative keratitis  
d. Stromal keratitis  
e. Epithelial keratitis
32. 6. What type of a hypersensitivity reaction is involved in scleritis?  
33. a. type I  
b. type II  
c. type III  
d. type IV
34. 7. What is the most severe form of scleritis?  
35. a. Diffuse  
b. Nodular  
c. Necrotizing  
d. Posterior
36. 8. Which of the following is not correct about the features of scleritis?  
37. a. Most common in the fourth to sixth decades  
b. Most common presenting symptoms are pain and redness  
c. In 20 % of cases it is bilateral  
d. The color is violaceous red  
e. Due to scleral edema the slit light beam is displaced forward
38. 9. Posterior scleritis cases should be differentiated from:

- 39. a. Orbital pseudotumor
  - b. Thyroid ophthalmopathy
  - c. Choroidal hemangioma
  - d. Uveal effusion syndrome
  - e. All of the above
- 40. 10. The anterior segment angiography of a scleritis case reveals:
- 41. a. Early leakage into the extravascular space
  - b. Venular obstruction
  - c. Arteriolar beading
  - d. Distortion of normal radial pattern of episcleral vessels
  - e. All of the above

42. **ANSWERS FOR NECROTIZING SCLERITIS REVIEW**

- 43. 1. C (Reference: Ophthalmology 1995; 102:687-692)
- 44. 2. A (Reference: Ophthalmology 1995; 102:687-692)
- 45. 3. A (Reference: Diseases of Sclera & Episclera. Duane's Clinical Ophthalmology)
- 46. 4. D (Reference: Surv Ophthalmol 1988 32:297-316)
- 47. 5. C (Reference: Semin Ophthalmol 1995; 92:1436)
- 48. 6. C (Reference: Ophthalmology 1991; 98:462-479)
- 49. 7. C (Reference: Br J Ophthalmol 1976; 60:163-191)
- 50. 8. C (Reference: Australia & New Zealand Journal of Ophthal 1988; 16:169-176)
- 51. 9. E (Reference: Foster CS, Sainz de la Maza M. The Sclera. Springer-Verlag, New York 1994, pp. 120-124)
- 52. 10.E (Reference: Watson PG. Atlas of the Sclera. Mosby-Volfe 1995. pp 117-120)
- 53.