

Ophthalmic Whipple's Disease

Roxanne Y. Chan, M.D.

Case Presentation

Chief complaint. The patient is a 53-year-old white female, who has a history of endometrial carcinoma for 15 years, presented to us in December 1996 with a two-month history of chorioretinitis, vitritis, and cystoid macular edema.

History of Present Illness. One week after camping at Lake Winnepesaukee, New Hampshire in October 1996, the patient developed a severe gastrointestinal "flu" and an erythematous right foot and leg rash, which resolved in two days. Two weeks later, there was an onset of floaters and diminished vision in the patient's right eye. She sought the attention of her ophthalmologist, who diagnosed uveitis O.D. and treated her with 1% prednisolone sodium phosphate drops with improvement. However, the uveitis relapsed when the corticosteroid was tapered.

Medications. 1% prednisolone acetate drops four times a day in the right eye; prednisone 20 mg P.O. every other day.

Review of Systems. Significant for chills, night sweats, fatigue, right face numbness, cervical arthritis, painful, swollen and stiff joints, muscle aches, history of measles and mumps, cat owner, smoker, used birth control pills.

Examination.

Visual acuity

20/70 O.D.; 20/20 O.S.

Slit lamp examination

significant for 2+ cells in the anterior chamber and vitreous O.D.; O.S. normal

Applanation tonometry

13 mm Hg O.D.; 16 mm Hg O.S.

Dilated fundus examination (Fig. 1 and 2)

subtle retinal vasculitis

retinal pigment hyperplasia in the inferomedial fundus

very faint, small white choroidal lesions in the periphery

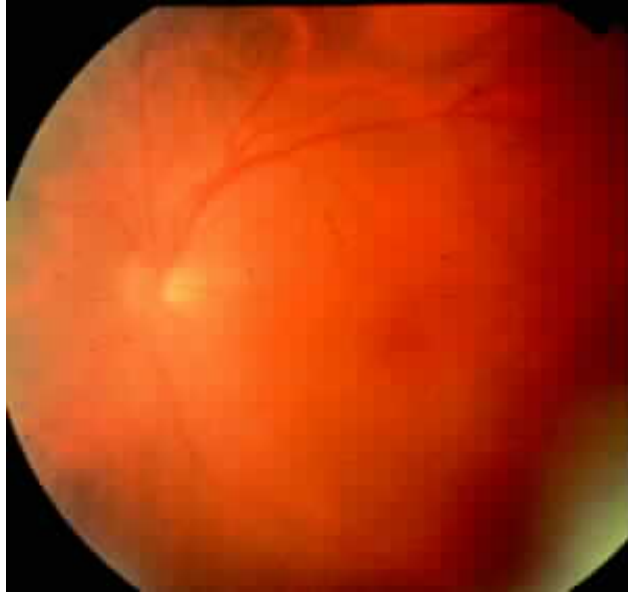

Figure 1

Laboratories.

CXR: small, nodular density in the right apex (small calcified granuloma, per radiologist).

Normal: SPEP, RPR, FTA-ABS, VDRL, EKG, Lyme and toxoplasmosis titers, PPD, CBC

ANA 1:16, ACE 53

HLA-B27 negative

Differential. The disease is a great mimic and should be suspected in individuals with the four most prominent symptoms: weight loss, arthralgias, diarrhea and abdominal pain. If the arthralgias precede the other symptoms by a period of months to years, the diagnosis deserves very serious consideration. All of these diseases involve multiple organs and are associated with protean manifestations.

Sarcoidosis. Iris nodules and greasy keratic precipitates similar to sarcoidosis (Rickman 1992), a systemic granulomatous disease with characteristic histopathology of noncaseating granulomas like those of Whipple's disease, may develop. This clinical resemblance to sarcoidosis may be due to antigenic and structural similarities and has caused confusion in a number of cases.

However, posterior segment manifestations are less common, such as retinal perivasculitis and deep yellow choroidal granulomas.

Malignancy, including such as primary intraocular lymphoma or metastatic (this patient had a history of endometrial carcinoma), may present with floaters, cells, KP, and/or yellow subretinal infiltrates. Blurry vision is less consistent with carcinoma.

Collagen-vascular disease, such as Lyme, may have a rash, KP, and vasculitis.

Patients with ***Mycobacterium-avium-intracellulare*** usually present without visual changes, creating 50 to 100 m m lesions throughout the fundus. Numerous PAS-positive granular macrophages are misleading with *Mycobacterium avium-intracellulare complex (MAC)*, histoplasmosis, and macroglobulinemia. However *MAC* is acid-fast, easily cultured, has a different electron microscopic appearance, and is an opportunistic infection found in patients with immunodeficiencies (ie. AIDS). Concomitant *MAC* and Whipple's disease has been reported (Dobbins 1987, Maiwald 1995). The semisynthetic rifamycin, rifabutin, used to prevent and treat *MAC* in AIDS patients may result in anterior uveitis, hypopyon, or retinal vasculitis (Arevalo 1997), especially if used with clarithromycin or fluconazole (Saran 1994).

Patients with ***systemic histoplasmosis*** usually have a clear vitreous, "histo spots," maculopathy, and peripapillary pigment changes. Under electron microscopy, histoplasmosis appears large, round, encapsulated and located in macrophages.

Amyloidosis, tuberculosis, white-dot syndromes (covered in a future presentation), ***birdshot*** are also possible. Whipple's disease may masquerade as amyloidosis, which may be associated with underlying multiple myeloma and stains positive with Congo red and methyl violet.

Diagnostic Vitrectomy (12/30/96). The vitreous sample was sent for cytology and polymerase chain reaction (PCR). Cytology revealed chronic inflammation and no evidence of malignant cells. PCR was negative for HSV, VZV, CMV, Lyme, toxoplasmosis, tuberculosis but had PCR had amplification product from the oligonucleotide primers specific for *Tropheryma whippelii*.

Clinical Course. In January 1997, treatment with tetracycline 250 mg P.O. four times a day was initiated, with continuation of prednisone 20 mg P.O. per day. The patient relapsed March 1997 when her prednisone was tapered and she was placed on trimethoprim-sulfamethoxazole double-strength twice daily, with discontinuation of tetracycline. In April 1997, the patient presented with increased cloudiness for several days after her prednisone taper finished 4 days prior to reexamination. There were 3+ keratic precipitates and anterior chamber cells, 4+ vitreous cells, along with multiple, white choroidal lesions 200-300 m m in diameter and slightly tortuous veins. She was treated with Kenalog and Vexol. In May 1997, the patient was improved, without cells. Depigmented, deep retinal areas were seen (Fig 3). The fluorescein angiogram were also significantly improved compared to January 1997.

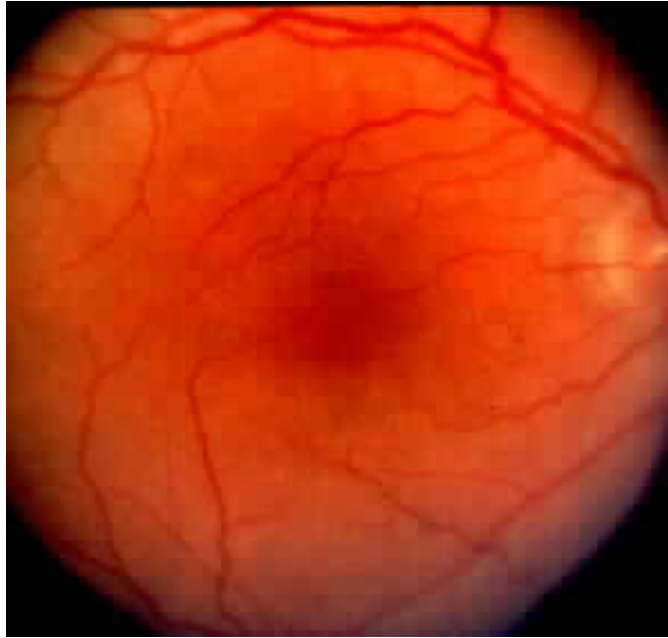


Figure 3

Case Summary. Whipple's disease is a rare cause of uveitis. Systemic clues and tissues samples can be invaluable in making the diagnosis so that treatment for the bacterial infection with antibiotics that penetrate the blood-retina and blood-brain barrier are initiated.

Ophthalmic Whipple's Disease

Definition. Whipple's disease is rare, multivisceral, and chronic, whose clinical presentation is typically dominated by a symptom triad of diarrhea, weight loss and malabsorption. However, digestive symptoms are often preceded for months or years by other symptoms, the most common being arthralgia, although cardiovascular, neurologic or pulmonary involvement may be more prominent at times.

Historic Aspects. Allchin and Hebb reported the first Whipple's disease case in 1895; however, they did not realize that their patient had a unique disease. George Hoyt Whipple in 1907 recognized the first case of the disease that now bears his name, when he reported a 36-year-old physician with "a gradual loss of weight and strength, stools consisting chiefly of neutral fat and fatty acids, indefinite abdominal signs, and a peculiar multiple arthritis." (Whipple 1907).

Epidemiology. Dobbins analyzed 676 patients and found that the systemic incidence rate is fewer than 18 cases per year (1960's) and 30 per year (1980 to 1986); however, the population also doubled between these time periods (1987). There is no accurate estimate of prevalence or death rate due to this low incidence rate. Deaths from Whipple's disease are usually a result of lack of antibiotic treatment, central nervous system or cardiac complications, delayed initiation of treatment (terminal disease), failure to diagnose the disease, and irreversible relapse. Few patients with systemic disease have ophthalmologic manifestations; Dobbins found that 19 of his 676 patients had ocular involvement (1987).

Of the 676 patients analyzed, only 15 were not Caucasian; 66% were farmers, construction workers or machinists (Dobbins 1987). The reported systemic Whipple's disease age range is 3 months to 81 years (Comer 1983). The age of diagnosis increased progressively until the 5th decade and then diminished in males, whereas it was uniform in the 4th to 6th decades with the maximal rate of diagnosis in the 7th decade in females (Dobbins 1987). There is an well-known but unexplained male predominance. It is unknown whether eye patients present at an earlier or later age than patients with systemic manifestations only.

Pathogenesis. Although the source of transmission is unknown, direct bacterial invasion has been found in numerous cases in various sites, including the eye. The bacteria most commonly invades the intestinal lamina propria and the vacuoles of "foamy" macrophages; less frequently, they are found in other intestinal mucosal structures, such as polymorphonuclear cells, smooth muscle, capillaries, lymphocytes, plasma cells, and mast cells. The route of invasion is via the lamina propria and basal intercellular spaces, rather than the intestinal lumen. There may be little or no injury to cells that uptake the bacteria (Rickman 1992). Apparently, the low-virulence bacteria are able invade with little provocation of the host immune system. Noncaseating granulomas, a localized inflammatory response to persistent antigen, are found in surprisingly few patients (less than 10%), given the number of bacteria usually present in pathology samples (Dobbins 1987). There may be some difficulty in phagocytosis or degradation of the intracellular gram-positive bacteria (Dobbins 1987). Macrophage and T-helper cell interaction results in the release of IL-2 and γ -IFN to activate macrophages to destroy their intracellular pathogens. The notion of a possible macrophage activation cell-mediated defect is supported by experiments performed by (Fredricks 1997), who was able to deactivate phagocytes with IL-4 (also IL-10 and dexamethasone) and render them permissive to intracellular Whipple's bacillus propagation. This Th2-like cytokine profile shows that host factors, such as Th1-Th2 imbalance, may play a role in disease pathogenesis. Cell-mediated deficiencies secondary to methotrexate (Cooper 1994), corticosteroids, AIDS (Maiwald 1995), leukopenia may have predisposed some patients to relapse. Severe malnutrition in exudative enteropathies, which may result in secondary temporary immunodeficiency and immunoglobulin loss and the transient anergy that commonly occurs in many infectious diseases resolves with antibiotic therapy. However, despite possible macrophage deactivation, there is little evidence that bacteria remain viable and reproductive intracellularly and the pathogenesis of Whipple's disease remains obscure.

Systemic Features. The four most prominent presenting manifestations are weight loss, diarrhea, migratory arthralgia, and abdominal pain. Digestive symptoms may be preceded for months to years by non-GI symptoms, most commonly migratory, seronegative, nondeforming arthralgias. Less frequent presenting manifestations include chills, fever, cardiovascular symptoms, and central nervous system abnormalities.

Although both systemic and ocular Whipple's disease are rare, they are well-described. G.H. Whipple first described a patient characterized by "a gradual loss of weight and strength, stools consisting of neutral fat and fatty acids, indefinite abdominal signs, and a peculiar multiple arthritis." Weight loss and diarrhea are observed less frequently in patients who are diagnosed prior to age 40. The weight loss generally appears in the year prior to diagnosis (usually 20-30 pounds). Early GI symptoms are nondescript, often diagnosed as IBD. Diarrhea has the features of steatorrhea but may be watery. Abdominal pain is nondescript but tends to be epigastric and exacerbated following meals. Arthralgias are transient, migratory, recurring, grossly symmetric, nondeforming and multiple, and may be present intermittently for many years before diagnosis (especially if there is fever or persistent lymphadenopathy), is of varying severity and rarely associated with effusions or inflammation without radiological changes. Arthritis most often oligoarthritis which involves the major limb and girdle joints. Late terminal GI disease may include fever, weight loss, diarrhea and steatorrhea.

These unusual presentations may include signs and symptoms such as arthralgias, abdominal pain, increased skin pigmentation, lymphadenopathy (including mediastinal widening), chronic

nonproductive cough, pleural effusion, chest pain from pleuritis, murmurs. CNS and cardiac findings are the most common besides the gut. Nonocular CNS findings may also occur without systemic involvement, consisting primarily of dementia, headaches, meningitis, myoclonus, seizures and somnolence. There is generally concomitant gastrointestinal involvement with CNS. 10% are diagnosed by clinical presentation; however, probably all patients with Whipple's disease have CNS involvement but just are not clinically obvious. In one report, 43% had CNS colonization without neurologic signs (Fleming 1988).

Uveitis. All of the clinical eye manifestations are nonspecific, including glaucoma, chemosis, retinal hemorrhage, papilledema, fibrovascular pannus, corneal ulcers, optic atrophy, and epiphora. Other patients have minimal intestinal symptoms with predominant ocular manifestations, leading to unfortunate delays in establishing the diagnosis (Avila 1984, Durand 1984, Gaertner 1980). Histopathologically, PAS positive macrophages have been demonstrated in the eye at autopsy, in vitrectomy specimens leading to the diagnosis in some patients. Font 1978 found that PAS-positive macrophages were present throughout the inner retina and vitreous and electron microscopic studies displayed intracytoplasmic degenerating rod shaped bacteria and membranous structures identical to those seen in the intestine, heart, and other tissues. Gaertner 1980 showed the presence of Whipple's bacilli by EM in a vitreous opacity removed from his patient 3 3/4 years before death and autopsy recognition of untreated Whipple's disease. From a diagnostic viewpoint, clinicians should include Whipple's disease in the differential diagnosis of patients with chronic bilateral retinitis and vitritis, especially if these disorders are associated with CNS manifestations (Dobbins 1987). In some patients, intraocular signs preceded CNS involvement, occurred in the absence of intestinal manifestations, and the diagnosis was made at autopsy; but still, you can count these in the back of your hand. Rickman reported one case of Whipple's disease of the eye, without clinically apparent CNS or gut involvement. The possibility that there may be eye involvement should also be entertained in the vast majority of patients who have typical Whipple's disease.

Our case had keratic precipitates and multiple 200 to 400 m m white choroidal lesions and macular edema. Retrobulbar neuritis, chemosis, keratitis, corneal ulcers, glaucoma, epiphora, fibrovascular pannus and retinal hemorrhage may also occur. Intraocular disease may precede CNS signs and symptoms without GI manifestations and could be diagnosed at or after autopsy (Knox 1995, Schwartz 1986).

Neuroophthalmology. Some authors believe as high as 43% (Fleming 1988) to all (Dobbins 1987) patients have central nervous system colonization without neurologic signs; this colonization may serve as a repository for bacteria and a mechanism for CNS relapse, the most common and devastating complication of Whipple's disease. CNS Whipple's disease is usually the source of the most devastating complications. Afflictions in the order of descending frequency are dementia, supranuclear ophthalmoplegia, myoclonus and hypothalamic signs such as dementia, insomnia, hyperphagia, and polydipsia. CNS ocular manifestations include ophthalmoplegia (predominantly supranuclear with occasional progression to total without response to head or caloric stimulation), gaze palsy and/or nystagmus. Myoclonus may be independent or with cranial musculature, eyes, jaws, and face involvement. Headaches, ptosis, seizures, and ataxia can also occur. Schwartz recognized in 1986 two cases of a proposed pathognomonic disorder named oculomasticatory myorhythmia (OMM), composing of pendular vergent oscillations or smooth vergent nystagmus associated with tongue and mandibular movements but no palatal myoclonus, and without association to saccadic effort, visual stimuli, or sleep (1984). The lesion has not been found yet. The fundamental characteristics of OMM are the high amplitude (5-25 degrees), low frequency (0.5-1.6 Hz) smooth continuous oscillations in the z-axis without palatal movement, relationship to saccadic effort, visual stimuli, or sleep. The CNS is also the most common site of relapse after antibiotic treatment. The possibility of central or peripheral eye involvement should be entertained in all patients who have systemic Whipple's disease.

Diagnosis. Many ophthalmic patients have a paucity of systemic manifestations (either primary or secondary to antibiotic treatment), making a proper diagnosis difficult. The diagnosis is challenging in the early stages of systemic or eye disease, and proper tests are always required to confirm clinical suspicion. Jejunal biopsy is most commonly used today; patchy or submucosal disease may result in negative initial biopsies. Although PAS-positive, diastase-resistant inclusions on light microscopy described by McManus 1946 and Black-Schaffer 1946 is sufficient in the gastrointestinal tract, biopsy of extraintestinal sites must be confirmed by noting the characteristic trilaminar cell wall on electron microscopy, as first demonstrated by Yardley and Hendrix in 1961, or by PCR. Since Whipple's disease is now known to be caused by a novel soil bacteria most closely related to an actinobacteria, was named *Tropheryma whippelii* and classified in 1992 by Relman in a duodenal sample according to PCR-sequenced bacterial 16sRNA, which has regions common to eukaryocytes and eubacteria and unique hypervariable regions particular to each species following repeated mutations. PCR represents a significant advance in the diagnosis of Whipple's disease and has been applied to duodenal tissue, lymph node, pleural-fluid cells, and peripheral blood; the diagnosis was made by PCR of a vitreous sample (Rickman 1992). PCR-detection of *T. whippelii* in tissue samples supports local bacterial infection rather than an immune-mediated process. Laboratories may reveal anemia in up to 90% of patients, usually that of chronic disease.

Treatment. Before the 1950's the disease was invariably fatal and continued to be largely so until the 1960's. The prognosis is grave without treatment, with the same significance as end-stage AIDS does today. Ander's treatment success with chloramphenicol was largely ignored until the hypothesis of an infectious etiology was confirmed with electron microscopy in 1960 and a series of studies (Trier 1965) removed doubts that antibiotics were the treatment of choice. The number of deaths and morbidity seem to have decreased with the use of antibiotics to treat this disease. Many antibiotics were used, most commonly tetracycline, which has good intracellular penetration but does not cross the blood-brain barrier. Although immediate results were described as spectacular, long-term results reviewed by Keinath in 88 patients in 1985 to determine the optimum antibiotic regimen showed that although antibiotics are effective, no one antibiotic is wholly curative due to central nervous system relapse, which often occurs many years after the original treatment. One year of TMP-SMX was recommended to penetrate uninflamed meninges and to decrease CNS relapse. None of sixteen patients with CNS manifestations relapsed on TMP-SMX (Vital Durand 1997).

REFERENCES

Arevalo JF, Russack V, Freeman WR. New ophthalmic manifestations of presumed rifabutin-associated uveitis. *Ophthalmic Surg Lasers* 1997;28(4):321-324.

Avila MP, Jalkh AE, Feldman E, Trempe CL, Schepens CL. Manifestations of

Whipple's disease in the posterior segment of the eye. *Arch Ophthalmol* 1984;102:384-390.

Comer GM, Brandt LJ, Abissi CJ. Whipple's disease: a review. *American*

Journal of Gastroenterology 1983;78:107-114.

Cooper GS, Blades EW, Remler BF, et al. Central nervous system Whipple's disease: relapse during therapy with trimethoprim-sulfamethoxazole and remission with cefixime. *Gastroenterology* 1994;106:782-786.

Dobbins WO. *Whipple's Disease*. Springfield, IL: Charles C. Thomas, 1987.

Durand DV, Lecomte C, Cathebras P, et al. Whipple disease: clinical review of 52 cases. *Medicine* 1997;76(3):170-184.

Fleming JL, Wiesner RH, and Shorter RG. Whipple's Disease: clinical, biochemical, and histopathologic features and assessment of treatment in 29 patients. *Mayo Clin Proc* 1988;63:539-551.

Fredricks DM and Relman DA. Cultivation of Whipple bacillus: the irony and the ecstasy. *Lancet* 1997;350:1262-1263.

Gaertner J. Whipple's disease of the central nervous system, associated with ophthalmoplegia externa and severe asteroid hyalitis. A clinicopathologic study. *Doc. Ophthalmol.* 1980;49:155-1987.

Knox DL, Green WR, Troncoso JC, et al. Cerebral ocular Whipple's disease: A 62-year odyssey from death to diagnosis. *Neurology* 1995;45:617-625.

Maiwald M, Meier-Willerson HJ, Hartmann M, and von Herbay A. Detection of *Tropheryma whippelii* DNA in a patient with AIDS. *J of Clin Microbiol* 1995;1354-1356.

Paulley JW. A case of Whipple's disease (intestinal lipodystrophy). *Gastroenterology* 1952;22:128-33.

Rickman LS, Freeman WR, Green WR, et al. Uveitis caused by *Tropheryma whippelii* (Whipple's bacillus) [brief report]. *N Engl J Med* 1995;332(6):363-66.

Schwartz MA, Selhorst JB, Ochs AI, et al. Oculomasticatory myorhythmia: a unique movement disorder occurring in Whipple's disease. *Ann Neurol* 1986;20:677-683.

Saran BR, Maguire AM, Nichols C, et al. Hypopyon uveitis in patients with acquired immunodeficiency syndrome treated for systemic *Mycobacterium avium* complex infection with rifabutin. *Arch Ophthalmol* 1994;112(9):1159-1165.

Trier JS, Phelps PC, Eidelman S, Rubin CE. Whipple's disease: light and electron microscope correlation of jejunal mucosal histology with antibiotic treatment and clinical status. *Gastroenterology* 1965;48:684-707.

Whipple GH. A hitherto undescribed disease characterized anatomically by deposits of fat and fatty acids in the intestinal and mesenteric lymphatic tissues. *Johns Hopkins Hosp Bull* 1907;18:382-91.