

# Phacogenic Uveitis

by Shawkat Michel, M.D.

Case presentation

C.C.

73 year old white male complains of a red painful right eye for one week.

HPI/POH

Perforating blunt trauma OD at the age of 9.(baseball bat)

Iritis OD :multiple episodes over many years, treated with local and systemic steroids.

One week before presentation, he suffered his worst attack of a red painful eye OD and had 3 iridotomies to relieve high pressure and pupillary block with iris bombe` ; he also had 2 local Triamcinolone Injections.

PMH

DM (NIDDM)

Hip surgery for aseptic necrosis of the hip joint (steroids)

Congestive heart failure

Bypass aortic surgery

Colonoscopy / polypectomy, -ve for cancer

Allergies: cortisone

Ocular Meds Systemic Meds

Prednisone OD QID Capoten

Maxitrol OD QID Glucotrol

Alphagan BID Lasix

Aspirin

Coumadin

Nitro

## **Ocular Examination**

VA : OD LP OS 20/25

Ta : OD 33 OS 16

Slit lamp biomicroscopy:

1+ conj injection OD

1+ lid edema OD

+dense corneal edema with bullae formation nasally

+uveal show nasally (the site of the old trauma )

AC: 2+cells, 2+flare OD+flocculent material OD:

the cells were characterized by being giant macrophages. In the inferior angle there was precipitation of material and inflammatory cells without a horizontal fluid level

Lens: +slightly dislocated intumescent cataract OD with a small break seen in the capsule

Left Eye: +mild NS otherwise normal

**Assessment:** Phacogenic Uveitis OD

## **Recommendation**

1- Cataract removal a.s.a.p.,

2- Aspirating the AC before entering the eye and examination of the aspirated material by cytopspin for lens-laden macrophages.

3- The lens should be removed intracapsularly and subtotal vitrectomy should immediately follow. 400 micrograms of decadron should be injected intravitreally after wound closure

Further to these recommendations the patient was operated upon by his local ophthalmologist : cataract extraction.

Postop course : uneventful.

An old choroidal rupture through the macula and a partial avulsion of the optic nerve limited vision to HM.

The above patient was referred to the Immunology and Uveitis Service for a second opinion , the referring ophthalmologist was of the opinion of doing enucleation. Although the eye suffered many episodes of anterior uveitis complicated by glaucoma, the etiology of this uveitis is a treatable one and once properly treated does not recur.

## Phacogenic Uveitis (Lens- induced Uveitis)

### Etiology

Unknown; possibly an autoimmune disorder

Tolerance for lens tissue is lost after trauma to the lens capsule, with consequent development of auto-antibodies and a possible granulomatous reaction with autoreactive T-cells

Triggering factors:

Perforating injury

Retained lens material after cataract extraction

Microtrauma of the capsule in mature cataract or after glaucoma surgery

Associated systemic conditions – none

### **Clinical Features**

Anterior Uveitis;

Granulomatous or non-granulomatous, (severity)

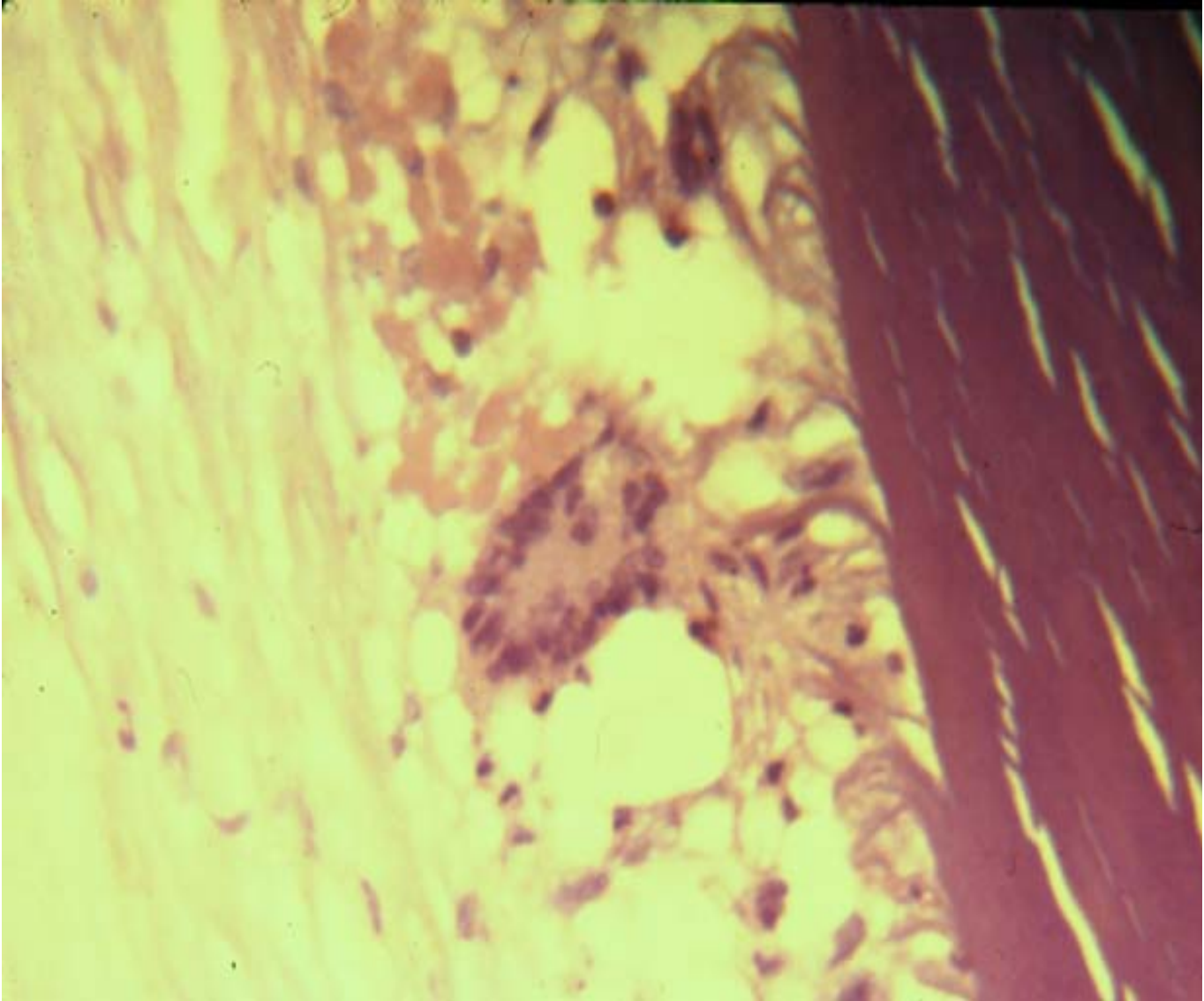
Can reportedly develop between 24 hours and 40 years after the causative event

A massive # of KPs, small and white in early stage, coalescing into large "Mutton fat" KPs

A thick A.C. exudate, opaque lens and rapid development of PS, abundant protein thick flare, cells and in some cases particulate lens material

The AC cells are characterized by being giant macrophages, full of phagocytosed lens material

Hypopyon or pseudohypopyon formation, made of lens material



**Figure 1.** Multinucleated giant cell surrounded by epithelioid cells on the anterior lens surface.

**Differential Diagnosis**

I- Sympathetic ophthalmia

II- Other causes of Anterior uveitis

III- Post-operative endophthalmitis, caused by *Propionibacterium acnes*; demonstration of the pathogen is helpful

Phacogenic Uveitis	Sympathetic Ophthalmia
initially unilateral	bilateral

anterior	anterior and posterior
usually but not always penetrating trauma	always penetrating trauma
usually lens fragments in AC	no lens fragments in AC and few cells in AC
no relapses after lens removal	Relapses characteristic
antigen: lens protein	antigen:retinal photoreceptor protein

### **Propionibacterium Acnes Endophthalmitis**

Chronic postoperative endophthalmitis

usually 3 months or more after extracapsular extraction

Granulomatous ( mutton fat KPs ), small hypopyon, mild vitritis, plaques on posterior capsule characteristic and may be residual lens material in capsular bag

Propionibacterium Acnes requires up to 2 weeks of incubation, samples of vitreous and post capsule should be obtained

Other causes of chronic post-operative endophthalmitis are S. Epidermidis ( between 2-6 weeks ) and fungal ( usually Candida 1-3 months )

In postop endophthalmitis with mild anterior uveitis and unclear etiology, treatment initially is frequent topical steroid; If no improvement, then AC and vitreous paracentesis, Gram and Giemsa stains, fungal, aerobic and anaerobic cultures.

### **Other causes of anterior uveitis**

- 1- HLA - B27 associated uveitis
- 2- JRA - associated iritis
- 3- Fuchs` heterochromic iridocyclitis
- 4- Herpetic iridocyclitis
- 5- Syphilis
- 6- Tuberculosis
- 7- Intraocular lens induced uveitis ( Uveitis Glaucoma Hyphema syndrome )
- 8- Posner - Schlossman syndrome
- 9- Traumatic iridocyclitis
- 10- Idiopathic anterior uveitis

Characteristic features of each of these causes of anterior uveitis

### **1- HLA - B27 associated uveitis**

About 50% of patients with anterior uveitis

more than half of these will have some type of spondyloarthropathy such as AS, Reiters and psoriatic arthropathy. Inflammatory bowel disease may also be associated

more commonly males in the second or third decade

severe nongranulomatous often with a fibrinous exudate, hypopyon and posterior synechiae

recurrences more common but the initial episode is the most severe

### **2- JRA - associated iritis**

most common disorder associated with uveitis in the pediatric age group

more common in the pauciarticular( less than 5 joints)

20 - 40% of the early onset, pauciarticular develop ch iridocyclitis and up to 60% of those are ANA positive ( 2 substrates )

10 - 20 % of late onset pauciarticular develop ch iridocyclitis and 75% of those are HLA - B27 +ve. RF is negative in both groups

bilateral nongranulomatous ch anterior uveitis associated with white quiet eye esp in early onset

Band shaped keratopathy and cataract

### **3 - Fuchs` heterochromic iridocyclitis**

2 - 5% of all cases of anterior uveitis and may represent an autoimmune reaction against iris pigment

usually ,but not always, in the lighter colored eye ; 7 - 15% have bilateral disease without heterochromia. Paradoxical cases with inflammation in the darker colored eyes occur.

Patients usually present with complications (cataract and glaucoma) because typical symptoms of ant uveitis are usually absent

stellate KPs throughout the cornea and iris stromal atrophy

often unresponsive to steroid; try intensive topical for one week but taper if no response

### **4 - Herpetic iridocyclitis**

stromal or epithelial corneal involvement usually, but not always, precedes

it can be acute, recurrent or chronic

Iris atrophy with transillumination defects characteristic

one of the causes of sclerouveitis

initially nongranulomatous but may become granulomatous with chronicity

### **5 - Syphilitic iridocyclitis**

secondary stage and late latent acquired syphilis

granulomatous or nongranulomatous

dilated capillary loops within the iris, called roseata, appear as red nodules

posterior segment involvement

Treatable disease

FTA-ABS or MHA-TP to confirm

### **Diagnosis**

### **6 - Tuberculous iridocyclitis**

the incidence is again rising ( AIDS )

granulomatous inflammation

PPD skin test and CXR in suspected cases

Syphilis and sarcoidosis should be ruled out

### **7 - Intraocular lens induced iridocyclitis**

more common with AC lenses but can occur with PC lenses

persistent postop inflammation

rule out infection and remnants of cortical material; Aqueous and vitreous aspirates

removal of the intraocular lens is often needed

### **8 - Posner - Schlossman Syndrome**

unilateral elevation of pressure ( up to 40 - 60 mm Hg ) and anterior uveitis

mild corneal edema and mild mydriasis

fine KPs and mild cellular reaction in AC

benign, and self-limiting course

during the attack topical beta blocker or mild miotic, topical steroids 2 - 4 times daily

### **Treatment of Phacogenic Uveitis**

Good response to treatment with a favorable

### **Prognosis**

Topical mydriatic and steroid drops and if necessary systemic NSAID, eg. ASA or Indomethacin

The cause should be removed: as much of the lens material as possible should be removed from the eye

If it follows extra-capsular extraction, treatment should continue until all lens material is absorbed; lens material that is not absorbed must be removed surgically

## **Phacogenic Uveitis**

**Vicente Victor D. Ocampo, JR, M.D.**

True or False

1. Phacogenic uveitis is believed to be an autoimmune disorder with production of autoantibodies which produce a break in the lens capsule.
2. Among the triggering factors in phacogenic uveitis is retained lens material following cataract extraction.
3. Analysis of cells taken from the anterior chamber of a patient with phacogenic uveitis reveals characteristic giant macrophages laden with lens material.
4. Phacogenic uveitis is always an acute ocular inflammatory process.
5. Phacogenic uveitis can be effectively controlled medically.

Modified Multiple Choice

For each item, write whether it describes

a. Phacogenic uveitis

b. Sympathetic ophthalmia

c. Both

d. Neither

1. Associated with penetrating trauma to the eye
2. Anterior and posterior uveitis
3. No relapses after lens removal
4. Associated with antigen to lens protein
5. Associated with antigen to retinal photoreceptor protein



Answer Key:

True or False:

1. False
2. True
3. True
4. False
5. False

Modified Multiple Choice:

1. C
2. B
3. A
4. A
5. B