

RECURRENT HERPES SIMPLEX KERATITIS IN PENETRATING KERATOPLASTY

NATTAPORN TESAVIBUL, M.D.

Abstract

Purpose and Methods: Penetrating keratoplasty (PK) in herpes simplex keratitis (HSK) is increasingly performed not only for visual purposes but also to remove viral antigen from the cornea and to reestablish the structural integrity of the eyes. With the improvement of medical management and surgical techniques which lead to a higher survival rate of the graft, PK in HSK still carries a high complication rate postoperatively. These complications include corneal graft rejection, herpes recurrences in the graft, persistent epithelial defect, corneal melting, secondary infection and graft failure. We present a case of recurrent HSK in corneal graft after prophylactic antiviral had been stopped. The role of postsurgical antiviral prophylaxis is discussed.

Conclusion: This case supports the use of prophylactic acyclovir 800 mg daily as an effective prevention of recurrent HSK and as a mean of reducing allograft rejection and graft failure after PK in HSK.

Case:

This is a case of a 67 year old white female who had a history of penetrating keratoplasty (PK) for herpes simplex keratitis (HSK) in the right eye. The patient's chief complaint was blurred vision and the concern of having another ulcer in her right eye. She had had recurrent HSK for 9 years and had penetrating keratoplasty 2 years ago. The patient had been taking Zovirax but had stopped and did not recall when.

Her past medical history revealed episodes of ileitis.

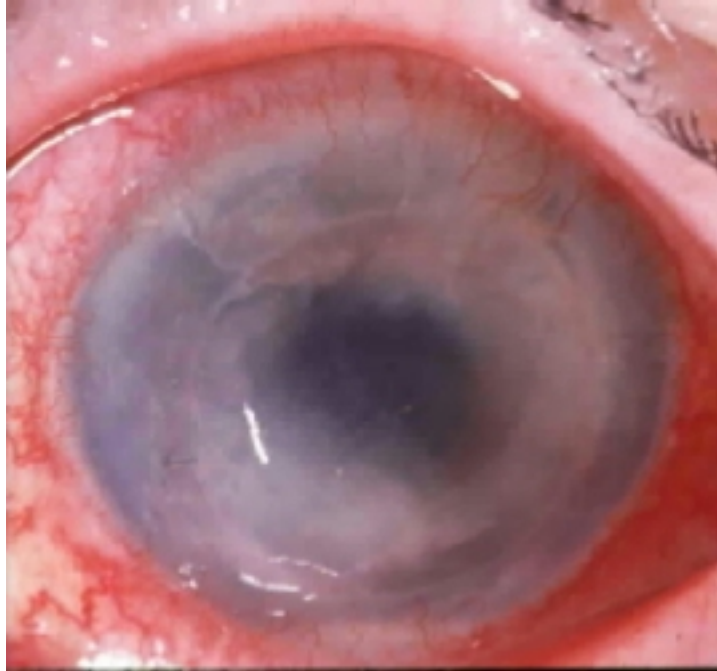Surgical history was an appendectomy at the age of 35 and a hysterectomy at 46.

Review of systems was unremarkable and there was no family history of ocular diseases.

Present ocular medications were: Bacitracin ointment once a day.

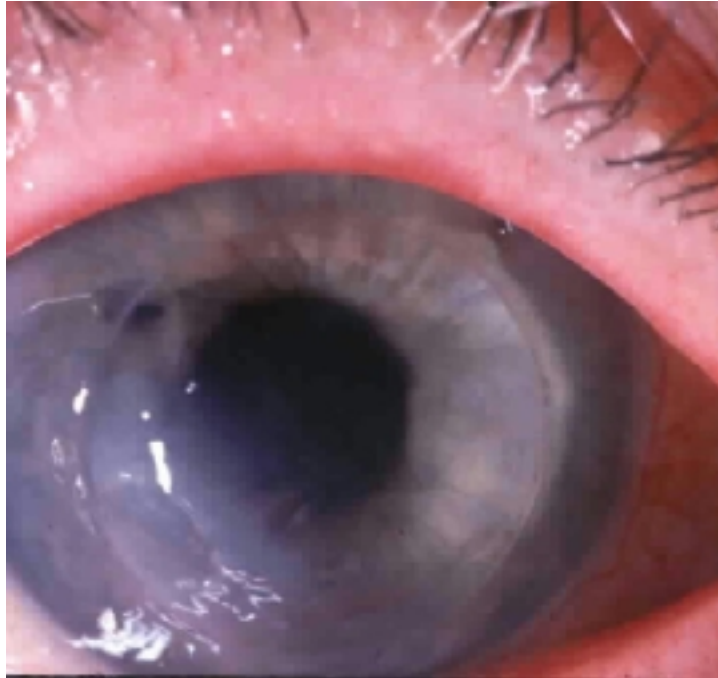
Eye examination at the first visit showed best corrected visual acuity of counting fingers in the right eye and 20/30 in the left. The intraocular pressures were normal. The conjunctiva was injected in the right eye with markedly decreased corneal sensation. Slit lamp exam showed an edematous corneal graft in the right eye with dendritic and geographic ulcers involving the graft and recipient cornea. The anterior chamber reaction could not be well evaluated due to the haziness of the cornea. The right eye had an intraocular lens. Posterior segment exam was unremarkable in both eyes. The impression at that time was active HSK in the penetrating keratoplasty graft. Zovirax eye ointment 5 times daily and Zovirax 800 mg per day orally were started.

At follow up 5 days later, best corrected visual acuity was hand motion in the right eye and 20/40 in the left. The patient was noted to have a geographic ulcer and corneal graft rejection as shown in the picture.



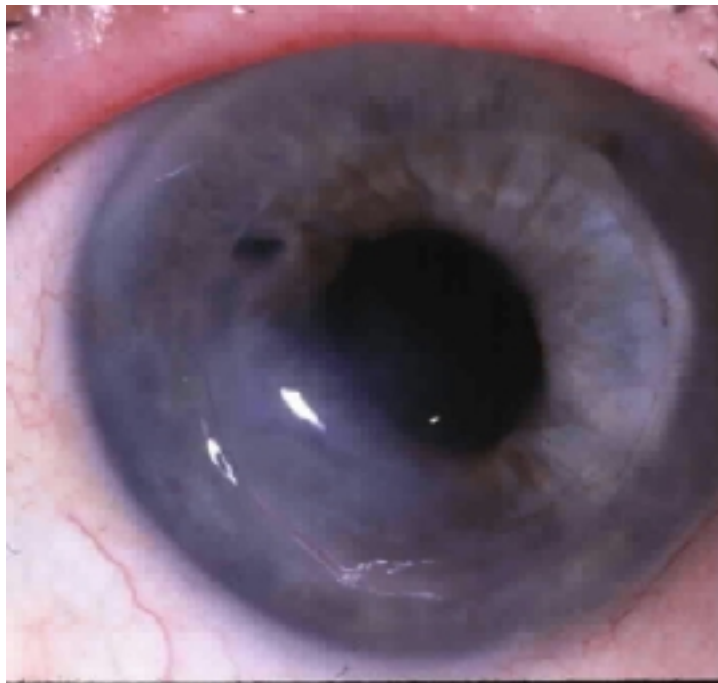Inflammase forte was prescribed concomitantly with Zovirax and the patient was re-evaluated 2 days later. At which time the eye was slightly more quiet the ulcer and the rejection had not spread further. An exposed suture was removed from the area of persistent epithelial defect. Topical steroids were slowly tapered over the next 5 weeks to a maintenance dosage of one drop a day.

On the next follow up 5 weeks later, best corrected VA had slightly improved to 20/400 in the right eye and 20/40 in the left. The epithelial defect was much smaller and the graft looked clearer as shown in the picture below.

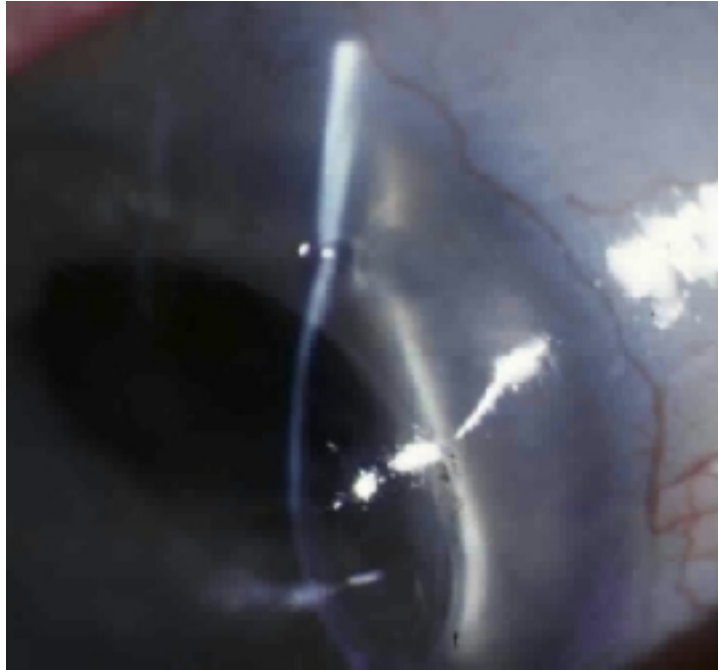


The patient was fitted with a bandage contact lens and Polytrim eyedrops were prescribed. Inflammase was maintained at once daily. Zovirax eye ointment was discontinued but the oral treatment was maintained.

After a week of bandage contact lens, the epithelial defect had healed nicely and the underlying stroma developed 50% thinning without any inflammation. Contact lens and Polytrim were discontinued. This picture below show the area of stromal thinning at the graft-host junction.



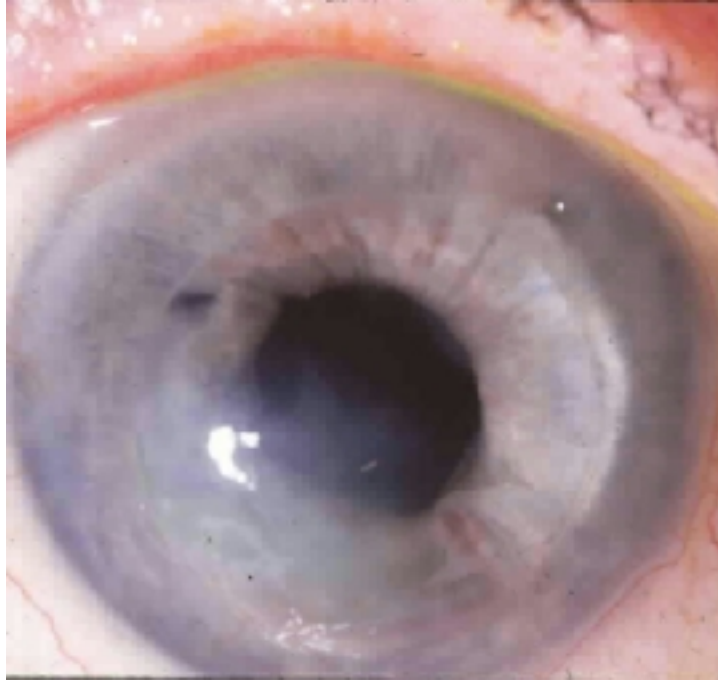A month later, the patient had an additional thin spot in the recipient cornea at 2:00 just posterior to the graft-host junction as shown below.



At this time, anticollagenase medications were prescribed and her treatment was:

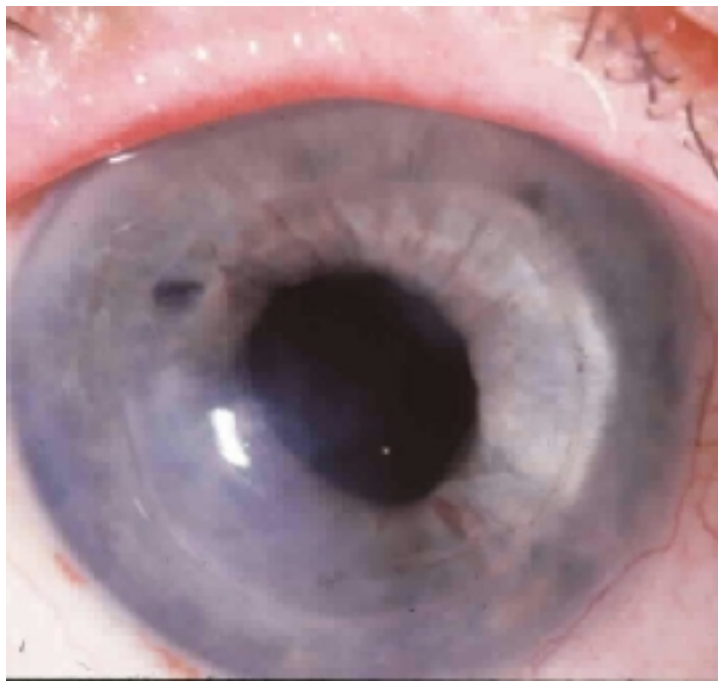Zovirax 800mg/ day
Doxycycline 100 mg /day
Provera eye drops every 2 hours

After 4 weeks of treatment , the patient had responded well with an acuity of 20/200 in the right eye. There was no progression of the thinning area and the eye looked quiet as demonstrated in the picture below.



Provera was tapered and switched to Inframase which was maintained at once daily.

The patient's eyes were stable for 6 months with best corrected visual acuity of 20/100 in the right eye and 20/50 in the left. The patient was noted to have blepharitis in both eyes but the conjunctiva looked quiet. The corneal graft was slightly edematous and hazy with a thinning area in the graft-host junction at 6-8:00. The picture below shows the right eye during the stable period.

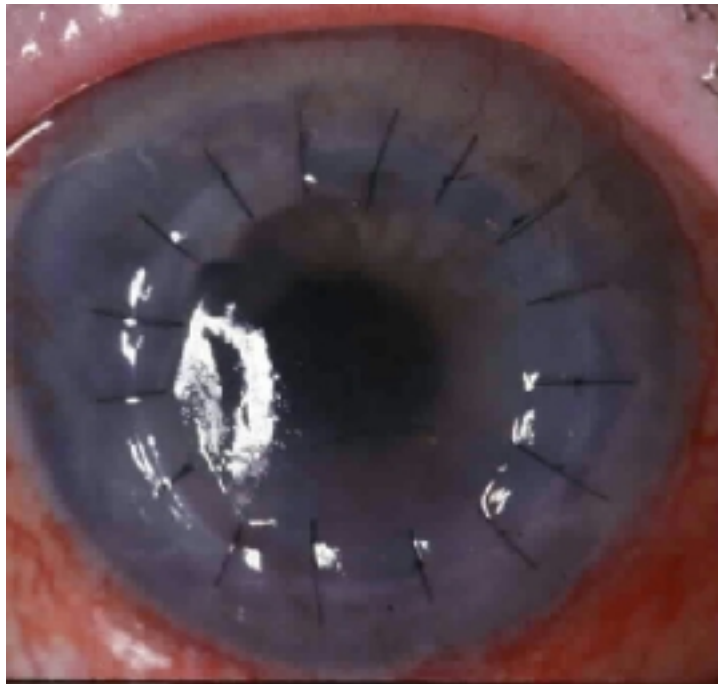


Her medications were:

Zovirax 800 mg/day
Doxycycline 100 mg/day for blepharitis.
Inflamase once daily

Repeat penetrating keratoplasty was performed in the right eye. Topical steroids were increased to every 2 hours and Polysporin ointment was prescribed at twice daily.

A week after the surgery, a corneal epithelial defect and stromal thinning developed on the graft-host junction at 6-9:00 as shown in the picture.



A tarsorrhaphy was performed and topical steroids were decreased.

The epithelial defect and corneal thinning were slowly improved after tarsorrhaphy and the graft was clear over the next 6 weeks. Topical steroids were slowly tapered to once daily.

The tarsorrhaphy was partially opened after 7 months and was completely opened 3 months after that. The graft was clear and compact with best corrected visual acuity of 20/70 OD and 20/40 OS. Her left eye at this point was noted to have developed a mild cataract.

16 months after the second keratoplasty and 7 months after opening the tarsorrhaphy, the patient still continued with her Zovirax 800 mg and Doxycycline 100 mg daily.

She also used topical steroids once daily and some artificial tears. The graft was clear and compact with best corrected visual acuity of 20/60 with 5 diopters of astigmatism at the 43 degree axis which corresponded with the previous area of thinning and scar formation.

DISCUSSION

Penetrating Keratoplasty in Herpes Simplex Keratitis

Introduction

Herpes simplex keratitis is a relatively infrequent indication for keratoplasty. However, PK in herpetic eyes is increasingly performed not only to improve vision but also to remove viral antigen lodged in the cornea and to reestablish the structural integrity of the eye(1).

This case illustrates an episode of recurrent HSK in the graft concomitant with graft rejection 2 years after penetrating keratoplasty.

Complications after transplantation in herpetic eyes are more numerous than complications after other transplantation. These complications include corneal graft rejection, as well as herpes recurrences within the graft, persistent epithelial defect, corneal melting, secondary infection and graft failure(2). All of the aforementioned problems have been known to increase the rate of corneal graft failure in herpetic eyes in the past. Success rates in the past ranged between 45% and 68% for active keratitis and 68% and 83% in inactive cases(3,4). Langston reported a clear graft success rate for at least 2-10 years postoperatively in herpetic eyes related to 1) Reduced inflammation 2) minimal deep vascularization 3) use of 10-0 nylon 4) use of high dose topical steroids postoperatively. The average recurrence rate of epithelial herpes in this study was 15 percent within 2 years and the rejection rate was lower in the high steroid dosage groups(5).

Since 1980s changes in the management of ocular herpetic disease have greatly improved the prognosis for PK. The improvement in surgical techniques, appropriate use of corticosteroids, antiviral medications either topical antiviral or systemic acyclovir, bandage soft contact lens and tarsorrhaphy have helped improve the success rate of PK in HSK(6,7). However, rejection and recurrent herpes are still the major causes of graft failure and grafts that had recurrence in the first postoperative year had a significantly increased risk of failure(7,8,9).

Role of postoperative antiviral prophylaxis

Early HSV recurrence affects the stability of the graft, making it prone to failure at a later date(8). This may be the result of loss of endothelial cells from the inflammation accompanying the recurrence(10). Moyes(8) determined the cause of graft failure in his study as following; rejection was the primary cause of loss of graft clarity 35%. Rejection combined with herpetic recurrence accounted for 20% and endothelial failure without recurrence or rejection 20%. Herpetic recurrence without rejection caused 10% and epithelial break down and/or microbial keratitis caused 15%.

The sensory neuron is known to be the principal site for HSV latency in humans and animals. After a primary ocular infection, HSV establishes a latent infection in the ganglia that innervate the eye. After endogenous or exogenous triggers, reactivated virus travels along the nerve to the end organ. Evidence is accumulating that nonneuronal cells may be capable of harboring latent virus which can be reactivated in situ to result in clinical disease (11,12). Recurrent HS epithelial ulcers after PK is the most common form of recurrent HSK (6,8) and occurs mostly at the graft-host interface which probably can be explained by the pattern of corneal re-innervation (6,13,14).

Prophylactic antiviral treatment after PK has been used for the purpose of minimizing recurrent herpes simplex keratitis. Ficker's study(6) showed 23% of corneal grafts that developed a herpetic recurrence will undergo an episode of rejection. However, the routine use of antiviral therapy in the early postoperative period has remained less widely recommended. Postoperative topical antivirals were used prophylactically when they first became available but were found to result in graft vascularization and persistent epithelial defects(1).

The overall rate of recurrent dendritic keratitis after transplantation for herpes was 19% as shown by Cohen(7). Cobo et al reported that withholding antivirals during the postoperative period did not result in a higher rate of early herpetic recurrence(15). However, Rose and associates (16)

showed that penetrating keratoplasty and postoperative steroids increased the reactivation of HSK in rabbits, and the study of Cobo et al showed a 32% of recurrent epithelial herpes developed after the treatment of graft rejection with steroid compared with 6% recurrence in non-rejection group, indicating the role of antiviral prophylaxis. He emphasized the need for antiviral prophylaxis concomitant with intensive topical steroid administration for graft rejection episodes because these could be complicated by HSK recurrence. Foster and Duncan routinely used prophylactic topical antiviral therapy and their recurrence rate was 6% after 2 years(17). Ficker et al reported the result of prophylactic topical antiviral therapy during the treatment of allograft rejection which reduced the recurrence following steroid treatment of allograft rejection from 34% to 1% and the failure rate from 39% to 21%(6). Moyes' study in 1994 confirmed this finding. This could be related to the effect of the antiviral medication in decreasing herpetic recurrence and attendant nonspecific inflammation that might aggravate an allograft rejection which can lead to graft failure.

Because of concerns of delayed wound healing and toxicity to the epithelium caused by topical antiviral treatment(1,18), Ficker et al concluded that oral acyclovir may have a role in postoperative treatment of patients who undergo keratoplasties for HSV keratitis.

Beyer demonstrated that acyclovir significantly lowered the incidence of HSV ocular shedding, epithelial ulceration and stromal keratitis in a rabbit autograft penetrating keratoplasty model (13)

Oral acyclovir in a dosage of 400 mg five times daily provides concentrations of acyclovir well above the minimum inhibitory concentration of HSV in tears and aqueous humor in humans (19), while chronic (up to 3 years) use of 800 mg daily has been proven to be effective in reducing recurrences of oral and genital herpes simplex (20,21). Barney and Foster first reported a prospective randomized trial of oral acyclovir after PK for HSK in 1994. They showed the efficacy of prophylactic oral acyclovir 400 mg twice daily in reducing the recurrence of herpes simplex keratitis and reducing corneal graft failure in patients who had a history of recurrent HSK and had undergone penetrating keratoplasty. The study showed no recurrences of HSK in any of 14 patients receiving acyclovir during a mean FU of 16.5 months compared with recurrences in 4 out of 9 patients (44%) without acyclovir during a mean FU of 20.6 months. Graft failure occurred in 2 out of 14 (14%) acyclovir treated patients compared with 5 of 9 (56%) without acyclovir(22). A study by Pavan-Langston showed that oral acyclovir 200 mg twice daily decreased the total number of recurrences of epithelial ulceration in 12 non-surgical patients from 39 recurrences in the 2 years prior to treatment to 3 recurrences in the 2 years after treatment was initiated(23). By implication from this study in non-surgical patients and the aforementioned studies in surgical patients, oral acyclovir would appear to be an appropriate antiviral prophylaxis for human penetrating keratoplasty after HSV keratitis, especially in a group where the risk of recurrence may be high.

Conclusion

Herpes simplex keratitis is a relatively infrequent indication for PK, and the management of these patients is challenging. With the improvement of medical management and surgical techniques which lead to a higher survival rate of the graft, penetrating keratoplasty in HSK still carries a high complication rate postoperatively. The major complications are recurrent HSK and allograft rejection. The case presented here supports the use of prophylactic acyclovir 800 mg daily as an effective prevention of recurrent HSK and as a means of reducing allograft rejection and graft failure after PK in patients with herpes.

References:

1. Pavan-Langston D. Viral diseases: herpetic infections. In: Smolin G, Thoft R, eds. Cornea, ed

3. Boston: Little, Brown, 1993:240
2. Pavan-Langston D. Viral diseases of the cornea and external eye. In: Albert DM, Jacobiec FA, eds. Principles and practices of ophthalmology: clinical and practice. W.B. Saunders, 1993: 117-61
3. Rice NSC, Jones BR. Problems of corneal grafting in herpetic keratitis. In: Jones BR, ed. Corneal graft failure: Ciba Foundation Symposium 15. Amsterdam: Elsevier, 1973; 221-39.
4. Polack FM, Kaufman HE. Penetrating keratoplasty in herpetic keratitis. *Am J Ophthalmol* 1972; 73: 908-13
5. Langston RHS, Pavan-Langston D, Dohlman C. Penetrating keratoplasty for herpetic keratitis. Prognostic and therapeutic determinants. *Trans Am Acad Ophthalmol Otolaryngol* 1975; 79: 577
6. Ficker La, Kirkness CM, Rice NSC, Steele ADMcG. The changing management and improved prognosis for corneal grafting in herpes simplex keratitis. *Ophthalmology* 1989; 96: 1587-96
7. Cohen EJ, Laibson PR, Arentsen JJ. Corneal transplantation for herpes simplex keratitis. *Am J Ophthalmol* 1983; 95: 645-50
8. Moyes AL, Sugar A, Musch DC, Barnes RD. Antiviral therapy after penetrating keratoplasty for herpes simplex keratitis. *Arch Ophthalmol* 1994; 112: 601-7
9. Epstein RJ, Seedor JA, Dreizen NG, et al. Penetrating keratoplasty for herpes simplex keratitis and keratoconus. *Ophthalmology* 1987; 94: 935
10. Musch DC, Schwartz AE, Fitzgerald-Shelton K, Sugar A, Meyer RF. The effect of allograft rejection after penetrating keratoplasty on central endothelial cell density. *Am J Ophthalmol* 1991; 111: 739-42
11. Pavan-Langston D, Rong BL, Dunkel EC. Extraneuronal herpetic latency: animal and human corneal studies. *Acta Ophthalmol* 1989; 67 ;192(suppl): 135-41
12. Cook SD, Hill JH. Herpes simplex virus: molecular biology and the possibility of corneal latency. *Surv Ophthalmol* 1991; 36(2): 140-8
13. Beyer CF, Arens MQ, Hill GA, Rose BT, et al. Oral acyclovir reduces the incidence of recurrent herpes simplex keratitis in rabbits after penetrating keratoplasty. *Arch Ophthalmol* 1989; 107: 1200-5
14. Skriver K. Re-innervation of the corneal graft. *Acta Ophthalmol* 1984; 62: 513-23
15. Cobo LM, Coster DJ, Rice NSC, Jones BR. Prognosis and management of corneal transplantation for herpetic keratitis. *Arch Ophthalmol* 1980; 98: 1755-9
16. Rose BAT, Beyer CF, Arens MQ, et al. Recurrent HSV-1 keratitis in rabbits after penetrating keratoplasty. *Invest Ophthalmol Vis Sci* 1988; 29(suppl): 453
17. Foster CS, Duncan J. Penetrating keratoplasty for herpes simplex keratitis. *Am J Ophthalmol* 1981; 92: 336-43
18. Langston RHS, Pavan-Langston D, Dohlman CH. Antiviral medication and corneal wound healing. *Arch Ophthalmol*. 1974; 92: 509-13
19. Hung SO, Patterson A, Rees PJ. Oral acyclovir in the management of dendritic herpetic corneal ulceration. *Br J Ophthalmol* 1984; 68: 398
20. Spruance SL, Stewart JC, Rowe NH, McKeough mB, et al. Treatment of recurrent herpes simplex labialis with oral acyclovir. *J Infect Dis* 1990; 161: 185
21. Kaplowitz LG, Baker D, Gelb L. Prolonged continuous acyclovir treatment of normal adults with frequently recurring genital herpes simplex virus infection. *JAMA* 1991; 265: 747
22. Barney NP, Foster CS. A prospective randomized trial of oral acyclovir after penetrating keratoplasty for herpes simplex keratitis. *Cornea* 1994; 13(3): 232-6
23. Pavan-Langston D. Herpetic keratitis: inhibition of epithelial recurrences with long term oral acyclovir. In: Proceedings of the New England Ophthalmological Society meeting, Boston, MA, Oct 21, 1992.

Recurrent Herpes Simplex Keratitis and Penetrating Keratoplasty

1. The features that pose special challenges to success of corneal grafting in a patient with herpes simplex keratitis (HSK) include:

a. Corneal neovascularization

- b. Corneal hypesthesia
- c. Corneal inflammation
- d. Recurrence of herpes simplex keratitis
- e. All of the above

2. The primary cause of graft failure in patients with a prior history of HSK is:

- a. Immunological rejection
- b. Primary endothelial rejection
- c. Secondary infection
- d. Persistent epithelial defect

3. The most frequent stimulus for corneal transplant rejection in patients who have received a transplant because of damage to the cornea from prior herpes simplex keratitis is recurrent herpes infection in the transplant:

True or False

4. Routine prophylactic topical antiviral therapy is not associated with corneal epitheliopathy and graft neovascularization.

True or False

5. Routine long-term (1 year or more) oral antiviral prophylactic therapy is associated with corneal epitheliopathy and graft neovascularization.

True or False

6. Routine long-term oral antiviral prophylactic therapy is associated with a reduced prevalence of herpes recurrence in the graft and a reduced prevalence of loss of graft clarity secondary to graft rejection.

True or False

7. An effective oral prophylactic dose of oral acyclovir for most patients following corneal transplantation for herpes keratitis scarring is:

- a. 200 mg/day
- b. 400 mg/day
- c. 600 mg/day
- d. 800 mg/day

Ans. 1e 2a 3T 4F 5T 6T 7d