

Retinal Vasculitis

Khayyam Durrani, M.D.

Case

A 44- year old lady presenting to us with a referring diagnosis of retinal vasculitis.

Past Ocular History

Approximately three years prior to presentation, the patient developed a gradual loss of vision in her left eye and noticed that 'pieces were missing from objects when viewed with the left eye. A diagnosis of 'pre-retinal fibrosis was made and symptoms persisted unchanged until about three months prior to presentation, when periorbital discomfort, a further decrease in vision, and an increase in the metamorphopsia involving the left eye developed. Vision in that eye was found to be 20/400, with elevated intraocular pressure, but no cells or flare in the anterior chamber. Periphlebitis was noted at the periphery of the left fundus, and macular edema and exudates observed. A diagnosis of retinal vasculitis and glaucoma, OS, was made. Complete blood count and blood chemistries were within normal limits, as were erythrocyte sedimentation rate and LE prep. ANA, however, was positive at 1:2560, with a speckled pattern. Within the next few days, the patient developed pain, redness, lid swelling and a foreign body sensation in the right eye, with no change in vision.

Past Medical History

About four years prior to presentation, the patient developed generalized arthralgias, increasing over time, and an episode of bursitis in the left shoulder requiring treatment by local steroid injection. This was followed nearly three years later by an episode of Achilles tendonitis and increasing fatigue, morning stiffness and arthralgias involving the fingers and knees, with occasional paresthesias involving the upper limbs. Approximately six months prior to presentation, the patient developed chronic diarrhea lasting approximately two months which resulted in an extensive but non-contributory work up. At the same time, she developed an aphthous ulcer on the roof of her mouth, which healed but was followed by a similar ulcer in the area of her right cheek.

Clinical Course

In view of her systemic symptoms, ocular findings and investigations, a diagnosis of possible SLE, manifest primarily as retinal vasculitis, and scleritis were made. Oral Prednisone was initiated at a dose of 80 mg, once a day, combined with topical Prednisone, four times a day in the right eye. Timoptic for the coincidental finding of glaucoma was also prescribed, two times a day in the left eye. Within approximately two weeks OS vision improved to 20/80-2, and although the eyes were white and quite externally and the macular edema had improved, the periphlebitis appeared unchanged on clinical examination. Prednisone was tapered to 40 mg once a day within two weeks. The patient developed abdominal pain, bloating, constipation, and facial swelling despite this decreased dose and led to a further reduction in dose to 20 mg a day over the next two weeks. This was accompanied by a gradual decrease in visual acuity, OS, to 20/100. Prednisone taper was continued, at 20 mg alternating with 10 mg for an additional week. Fluorescein angiography revealed persistent vasculitis involving the choroid shortly thereafter. Despite these findings, systemic steroid was tapered to 5 mg qod within the following month and replaced by Imuran, 100 mg per day. The patient was referred for further management.

Examination

Va 20/25 OD, 20/400 OS

IOP 17 mmHg OD, 20 mmHg OS

Slit Lamp Examination: Within normal limits OU

Fundus Examination

Within normal limits, OD

Extensive retinal vasculitis associated with retinal edema and cystoid macular edema, OS
Imuran was increased to 150 mg per day, with a view to continuing immunosuppression with no ocular flare-ups for a one-year period. Vision improved to 20/400 within about one month, and

ocular inflammatory activity ceased by that time. The patient developed increased arthralgias at about one month of follow-up but no recurrence of vasculitis was noted. Naprosyn, 25 mg TID was added at that time, and hemograms and liver function tests along with creatinine clearance monitored closely. Three months later, a mild elevation of AST to 52 and ALT to 107 was noted, and this resulted in a reduction of Imuran to 125 mg per day, following which enzyme levels returned to normal limits. Oral Prednisone was discontinued at seven months follow-up. This was closely followed by increased fatigue and arthralgias attributed to accompanying fibromyalgia by her rheumatologist and Amitriptyline was prescribed for this condition. Imuran was discontinued after one year of disease free activity. Final visual acuity was 20/20 OD and 20/70 OS, secondary to preretinal fibrosis in the left eye at one year follow up, with no recurrence of inflammation.

Introduction

Retinal vasculitis is most accurately defined as vascular leakage and staining of vessel walls on fluorescein angiography, with or without the clinical appearance of fluffy, white perivascular infiltrates in the eye with evidence of inflammatory cells in the vitreous body or aqueous humor (1). Inflammation involving the retinal vasculature may occur as an isolated finding unrelated to an identifiable underlying diagnosis, termed primary retinal vasculitis, or may be associated with a myriad of both ocular and systemic pathology. Management of retinal vasculitis requires a dualistic approach: one, to control ocular inflammation and reverse a potentially sight-threatening condition, and two, to spare no effort in identifying and treating concomitant, and in many cases, life-threatening systemic disease (1).

Clinical Characteristics

Retinal vasculitis most often manifests as a gradual, painless loss of vision. Floaters may be an associated symptom and indicates significant migration of leukocytes into the overlying vitreous. Photopsia is a less common presenting feature, as is reduced color perception, although the latter may indicate vasculitis surrounding the macula (2). In addition, large areas of central or paracentral scotomata may occur, corresponding to areas of retinal ischemia induced by vascular inflammation and subsequent occlusion. Vasculitis restricted to the peripheral fundus may be entirely asymptomatic (3). In addition to decreased visual acuity, visual field defects, and abnormal Amsler grid and color vision testing, examination may reveal related findings such as proptosis and scleritis as in Wegener's granulomatosis, abnormal ocular motility and an afferent papillary defect as in multiple sclerosis, elevated intraocular pressures in ocular toxoplasmosis, peripheral ulcerative keratitis and necrotizing scleritis in polyarteritis nodosa, anterior chamber cells and flare, as in Behcet's disease; an intermediate uveitis, and associated choroiditis or retinitis as in sarcoidosis, cytomegalovirus retinitis, and birdshot chorioretinopathy (3). Retinal vasculitis represents small vessel inflammation involving the arterioles, capillaries, and post capillary venules, either singly or in various combinations. Signs of retinal vasculitis involving the arterial side of the vasculature include attenuation, sheathing, and in some cases, cotton wool spots, representing micro-infarcts. Large parts of the superficial retina may become opaque secondary to terminal arteriolar occlusion. In contrast, vasculitis involving the venous side of the circulation produces retinal hemorrhage, edema, telangiectasia, and microaneurysms, although attenuation and sheathing may also be present (4). Similar findings occur in other conditions- atherosclerosis is a frequent cause of vessel sheathing, but is readily differentiated from vasculitis by the early vessel narrowing, lipid exudates, and increased light reflexes that occur in atherosclerosis. Attenuation occurs much later in retinal vasculitis, as do neovascularization, vitreous hemorrhage, and subsequent tractional retinal detachment (5). Active retinal disease manifests as fluffy white perivascular infiltrates; this transforms into perivascular fibrosis once quiescence is achieved. Detection of early disease activity, however, particularly during periods of remission, may require fluorescein angiography. Inflammation of blood vessels surrounding the macula and optic nerve head may give rise to macular edema, a common associated finding, and papillitis (4).

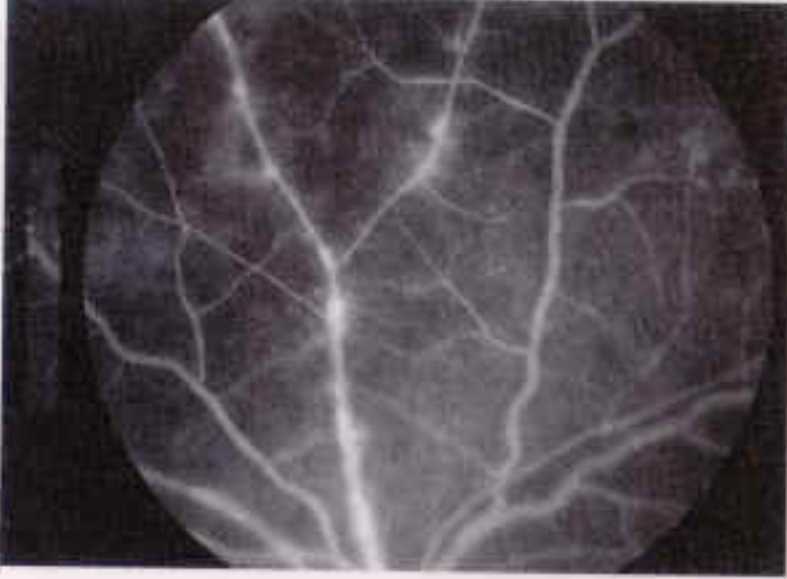


Figure 1 Fluorescein angiogram of a case of acute retinal necrosis showing focal arteriolar leakage

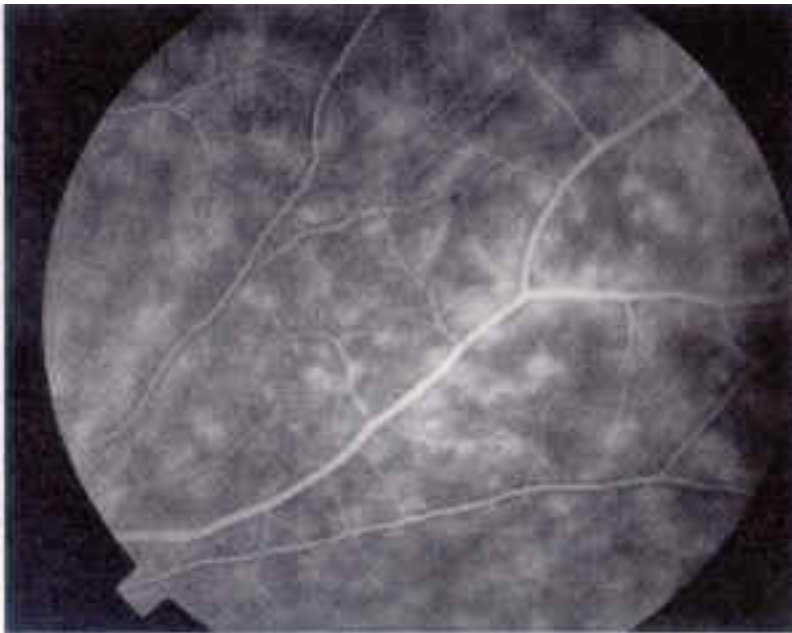


Figure 2 Fluorescein angiogram showing diffuse microvascular leakage (ferning)

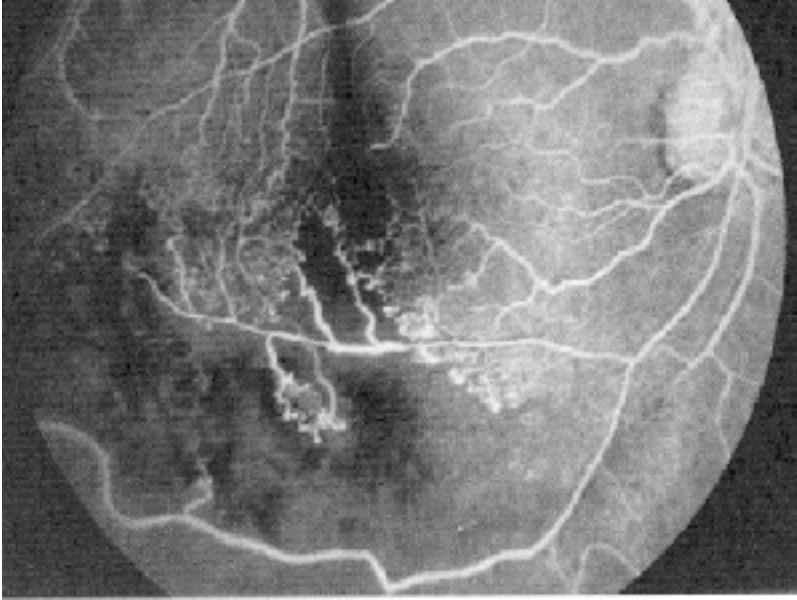


Figure 3 Fluorescein angiogram in a patient with Behcet's disease showing and inferotemporal ischemic branch retinal vein occlusion

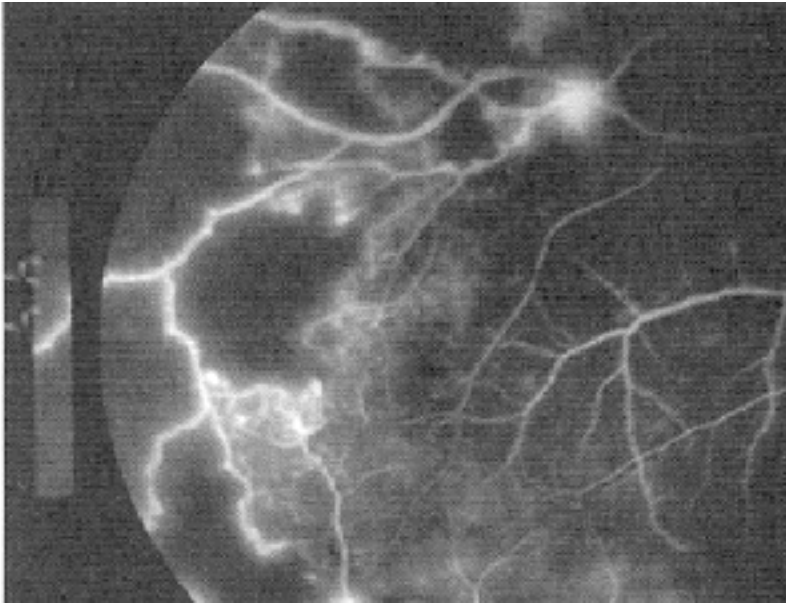


Figure 4 Focal dropout of the perifoveal papillary arcade indicative of macular ischemia

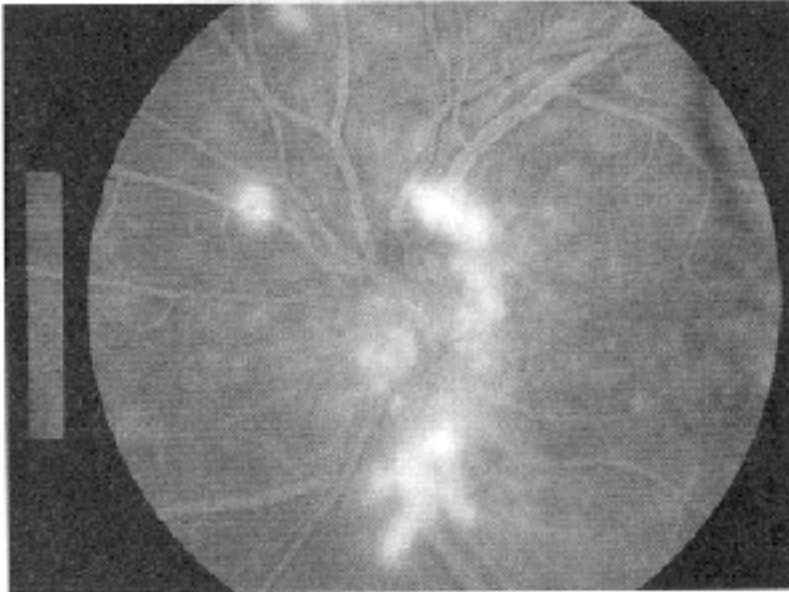


Figure 5 Neovascularization of the optic disk in a patient with sarcoidosis

Etiology

Retinal vasculitis may occur in the presence of ocular infection, ischemia or malignancy, in the context of a systemic inflammatory disease or as an isolated idiopathic condition.

	Systemic Vasculitis	Local	Infective	Masquerade
Systemic Inflammatory Disease				
Sarcoidosis	Systemic lupus erythematosus	Pars planitis	Metastatic endophthalmitis	Slow flow retinopathy
Behcet's syndrome	Wegener's granulomatosis	Birdshot retinochoroidopathy	Tuberculosis	Giant cell arteritis
Multiple sclerosis	Churg Strauss syndrome	IRVAN	Syphilis	Ocular lymphoma
Inflammatory bowel Disease	Scleroderma		Viral retinitis	Metastasis
Seronegative arthropathy	Relapsing polychondritis		Lyme disease	Retinoblastoma
			Cat-scratch disease	Melanoma
			Whipple's disease	Leukemia

IRVAN: Idiopathic retinal vasculitis, aneurysms, and neuroretinitis

Table 1 Associations of retinal vasculitis

There are a number of potential causes of retinal vasculitis. Most commonly, however, the disease is a manifestation of systemic disorders such as sarcoidosis, systemic lupus erythematosus, Wegener's granulomatosis, and Behcet's disease or as part of an ocular inflammatory condition, most commonly intermediate uveitis and viral retinitis (6). Less common is an isolated retinal vasculitis, in which no associated systemic or ocular disease can be identified. Brief descriptions of the five most common systemic associations with retinal vasculitis follow.

Wegener's Granulomatosis

A form of necrotizing vasculitis occurring more often in men above the age of 40, Wegener's granulomatosis most commonly presents as chronic sinusitis and rhinorrhea. Lung involvement, although frequent, is often asymptomatic but may present as acute bronchitis or, more rarely, hemoptysis. Nodules, infiltrates, and cavitations may be seen on chest X-ray. Glomerulonephritis occurs in 85% of patients, and is progressive, leading to renal failure and death if untreated (7). Forty to 50% of patients have ocular involvement, and this may precede other systemic symptoms. Proptosis and orbital pain occur most commonly, followed by scleritis, peripheral ulcerative keratitis, conjunctivitis, and dacryocystitis. Intraocular disease albeit less common, includes posterior uveitis, retinitis, and retinal vasculitis. Retinitis and retinal vasculitis may present as a geographic area of retinal edema and intraretinal hemorrhage, which can be difficult to distinguish from viral or parasitic retinitis (8). The disease should be suspected in patients with respiratory, renal, or central nervous system involvement and characteristic ocular findings. The diagnosis is supported by findings of pneumonitis or cavitory lesions on chest X ray, elevated white blood cell count, ESR, serum IgA levels, and a positive c-ANCA titer. Biopsy of involved tissue is often required to establish the diagnosis, and reveals a granulomatous vasculitis.

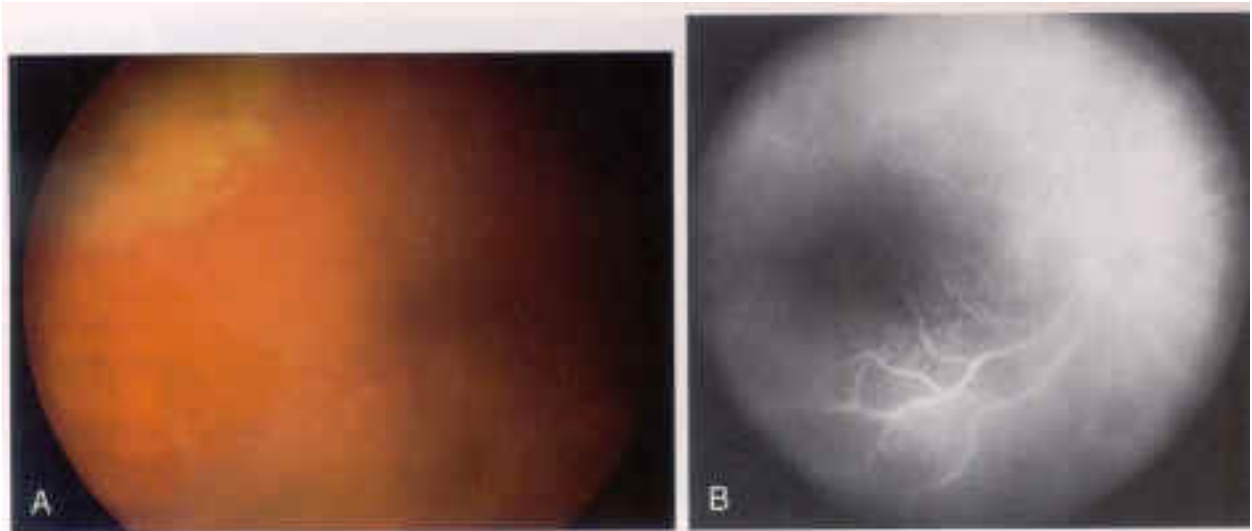


Figure 6 An area of retinitis and retinal vasculitis associated with biopsy-proven Wegener's granulomatosis. Fluorescein angiography illustrates an area of segmental vascular staining and leakage of dye into the vitreous

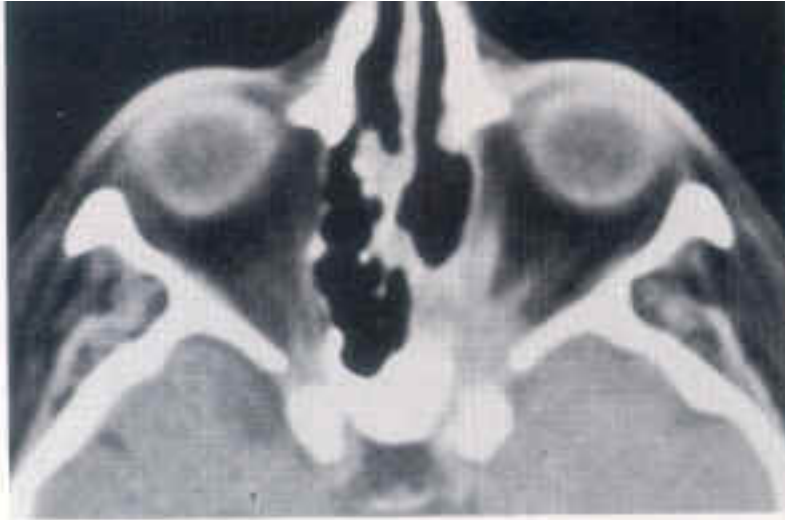

Figure 7 CT scan showing a mass at the left orbital apex extending into the cavernous sinus, with opacification of the sphenoid sinus. Biopsy of this tissue confirmed the diagnosis of Wegener's granulomatosis

Polyarteritis Nodosa

Clinically this immune complex disease involving medium sized muscular arteries presents with non-specific findings, including fever, malaise, weight loss and skin rashes. The process may affect any part of the body; renal involvement is found in 75% of patients and can lead to proteinuria, hematuria and renal failure, and can result in the almost pathognomonic finding of multiple aneurysms in the kidney on angiography. Cardiac involvement, occurring in 80% of patients, may lead to myocardial infarction, coronary arteritis and acute pericarditis. 60% develop mononeuritis multiplex (7). Cerebral manifestations are less common and include psychosis, hemiparesis, and brainstem lesions. Approximately 10 to 20% develop ocular involvement, and although peripheral ulcerative keratitis and iritis may be found in this disease, the most common findings in PAN are choroidal and retinal vasculitis. Central retinal artery occlusion, optic atrophy, and posterior scleritis have also been reported (8). Laboratory tests may show elevated white blood cell and eosinophil counts, decreased complement, elevated circulating immune complexes, and negative rheumatoid factor and ANA. Hepatitis B surface antigen is found in up to 70% of patients with PAN. Biopsy of an involved artery or lesion will demonstrate hemorrhagic vasculitis and fibrinoid necrosis, and clinches the diagnosis.

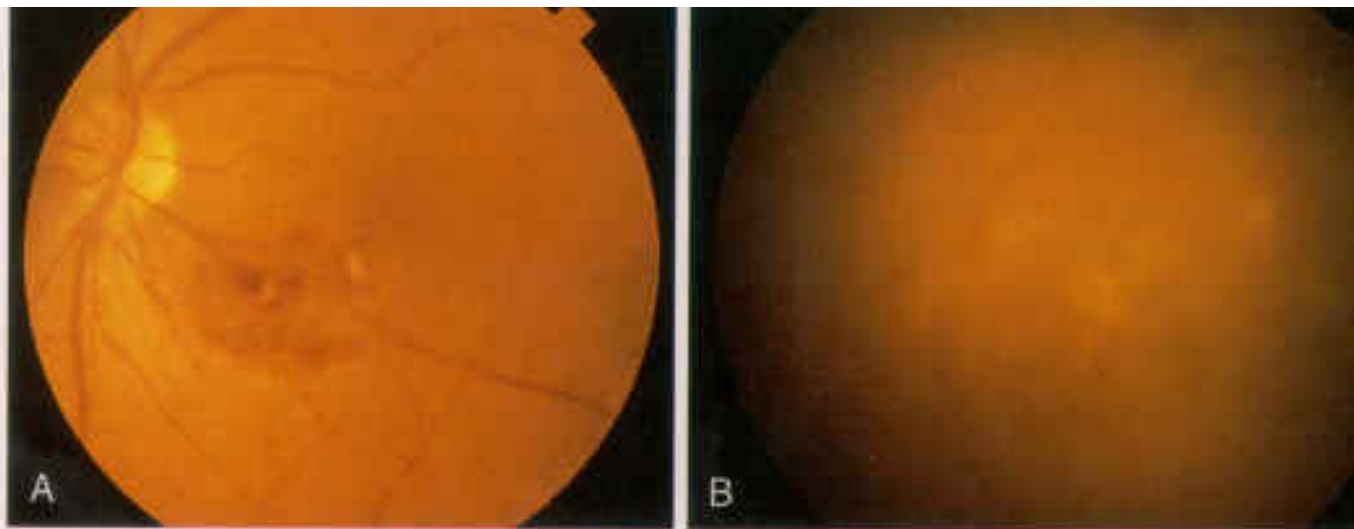


Figure 8 Localized area of necrotizing vasculitis associated with polyarteritis nodosa Systemic Lupus Erythematosus

Patients with this well-known disorder present with malaise, fatigue anorexia and low-grade fever. On examination, they may have arthritis, facial rash, alopecia and pleurisy; Raynaud's phenomenon, oral ulcers, and central nervous system involvement are also common (3). The 1982 Revised Criteria defines the disease by the presence of 4 of 11 major symptoms and signs. Although ocular involvement according to this system is not considered a diagnostic criterion, a presumptive diagnosis may be based on ocular and systemic findings and treatment instituted, as it has been seen that ocular involvement may precede overt disease in some cases, and delays in diagnosis or detection of relapse heralded by ocular involvement can lead to significant morbidity and even death (9). Laboratory testing typically reveals antinuclear antibodies, elevated circulating immune complexes, proteinuria, anemia, and in many cases a false positive VDRL result (8). Involvement of the eye occurs in up to 50% of cases, and may manifest as keratoconjunctivitis sicca, scleritis and keratitis, although the retina and choroid are most frequently involved, in the form of retinal or choroidal vasculitis. It is important to separate lupus associated retinal vasculitis from retinal changes occurring from the severe hypertension that may occur in lupus nephritis. Arteriolar narrowing, intraretinal hemorrhages, exudates, and disc edema are more characteristic of hypertensive retinopathy.

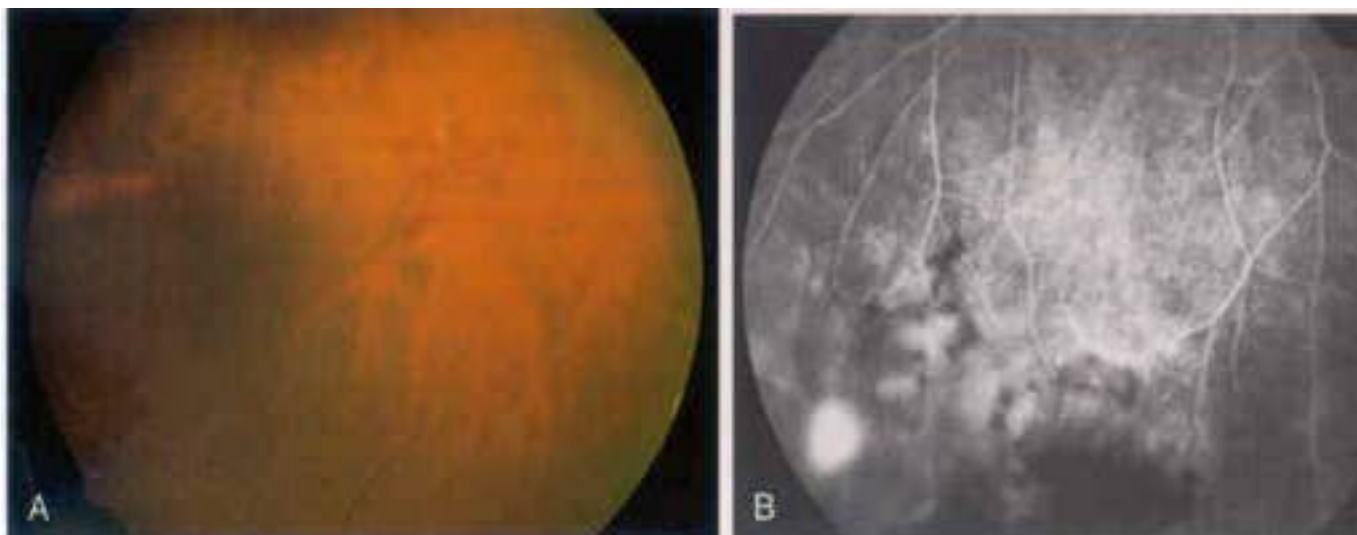


Figure 9 Peripheral retinal vasculitis in a patient with systemic lupus erythematosus with areas of intraretinal hemorrhage, retinal non-perfusion, and neovascularization on fluorescein angiography

Sarcoidosis

This disease typically affects young adults and usually presents with bilateral hilar lymphadenopathy and ocular and skin lesions. Diagnosis is based on clinical suspicion; although blood tests may show lymphopenia, a diffuse rise in gamma globulins, raised ESR and angiotensin converting enzyme levels and hypercalcemia (7). Uptake of radioactive gallium by granulomas may be demonstrated, and the Mantoux reaction is usually negative. Granulomas may be demonstrated by conjunctival biopsy in 50% and transbronchial biopsy in 70%. Most series report eye findings in about 25% of patients. The most characteristic finding is a periphlebitis, resulting in venous sheathing, macular edema, neovascularization. Deep yellow choroidal lesions consistent with Dalen-Fuchs nodules are seen in about 36% of patients and are thought to represent small choroidal granulomas that evolve and lead to secondary retinal pigment epithelial alterations. Optic disc swelling may arise secondary to uveitis, infiltration, as well as raised intracranial pressure (2).

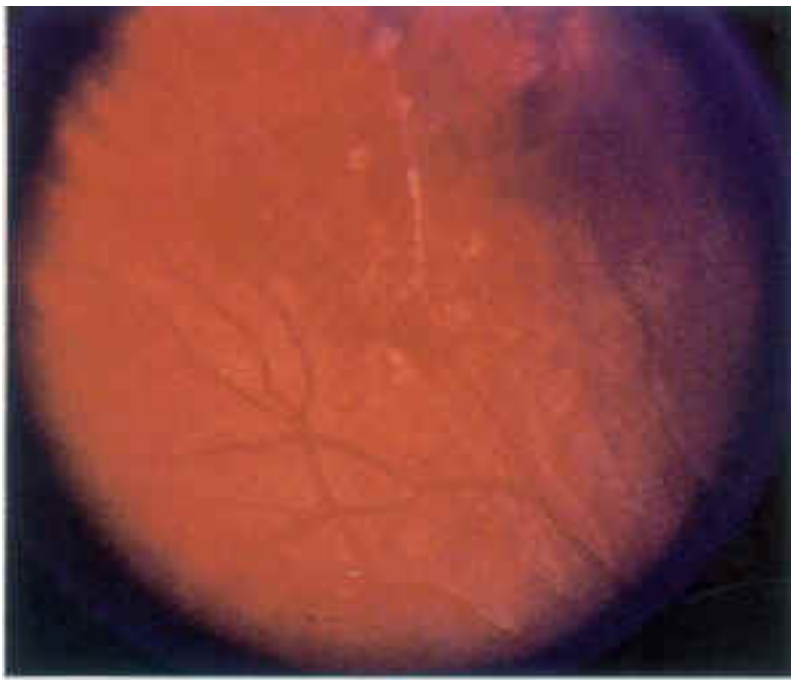


Figure 10 'Candlewax drippings' in sarcoidosis.

Behcet's Disease

This is diagnosed by the classic triad of recurrent aphthous ulcers, genital ulcers, and uveitis. Erythema nodosum, arthritis, and meningoencephalitis are also common. The complete form of Behcet's disease consists of oral ulcers, genital ulcers, uveitis, and non-ulcerative skin lesions, and criteria have been developed to describe partial or incomplete forms of the disease (8). Diagnosis is based on clinical findings. The eye may be the predominant organ involved in the disease and a nongranulomatous uveitis with hypopyon, posterior synechiae and hyphema are common. On fundus examination, vitritis, disc edema, are common- and retinal infiltrates in the presence of vasculitis and branch retinal vein occlusion may be predictive for Behcet's disease

(4).

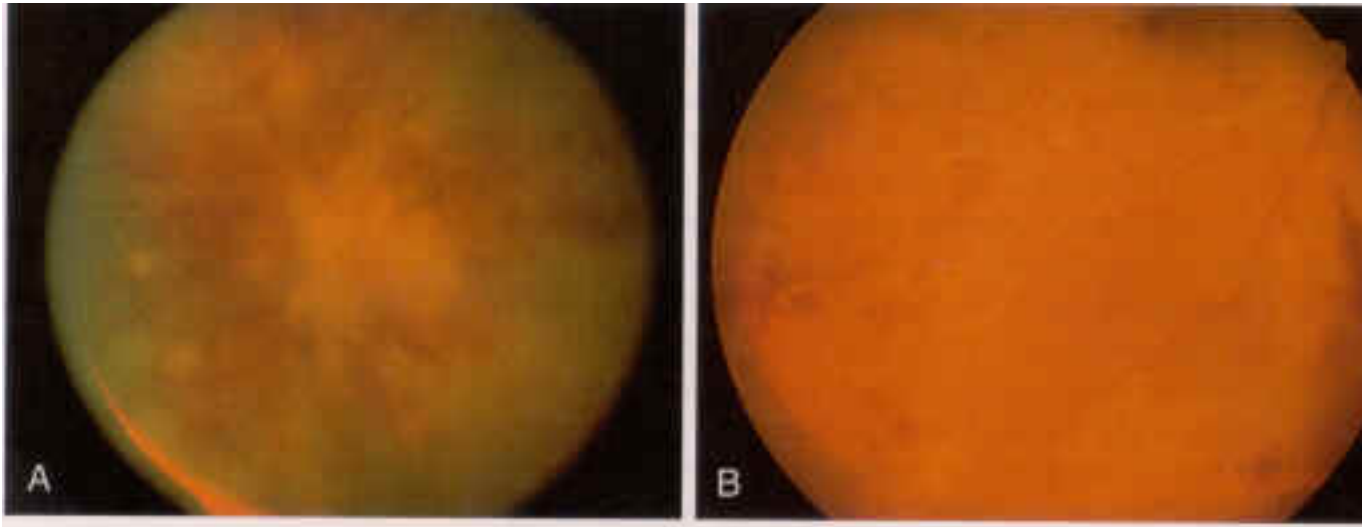


Figure 11 Two patients with Behcet's disease showing occlusive vasculitis, intraretinal edema, hemorrhage, and retinal non-perfusion

Diagnosis

The key to diagnosis in retinal vasculitis, as in all medical conditions, lies in an accurate and relevant history. When presented with a patient in whom vasculitis is suspected, specific questions about the presence of a possible multisystem inflammatory disorder should be asked. A history of orogential ulceration and skin rash (Behcet's syndrome), recent weight loss, dry cough, night sweats, lymphadenopathy or arthralgia (sarcoidosis), neurological symptoms (multiple sclerosis, sarcoidosis) arthritis (seronegative arthropathies), or recent change in bowel habit (inflammatory bowel disease) should be sought. Evaluation of patients with such multisystem disease may be guided, in part, by ophthalmic findings (10).

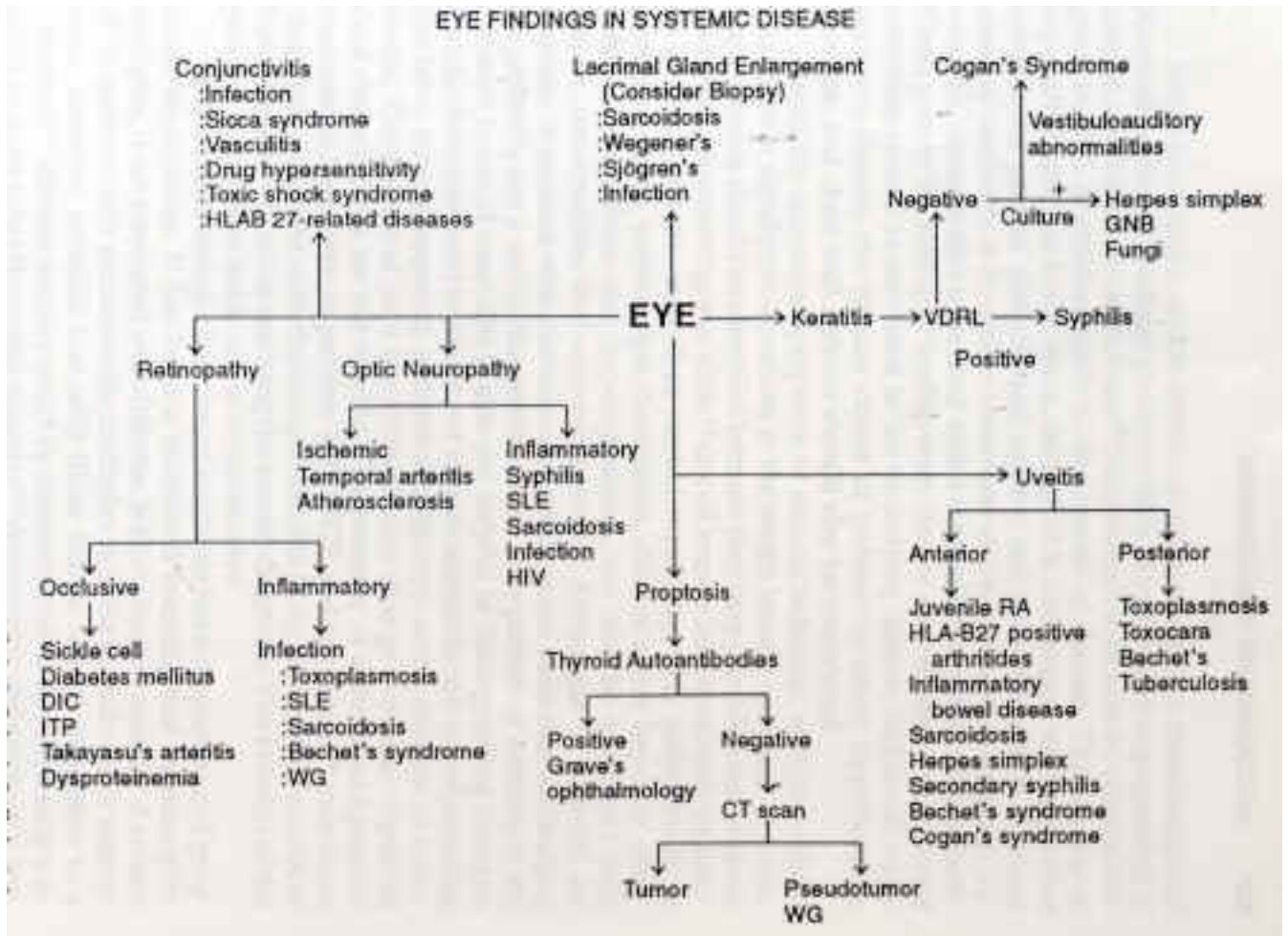


Figure 12 Evaluation of patients with multisystem disease and ocular abnormalities- a preliminary diagnostic algorithm

On examination, the most important clues to a diagnosis are the type of vessel involved. Arterial involvement almost always signifies a systemic vasculitis or viral retinitis. Capillary involvement suggests Whipple's disease, and involvement of retinal veins usually indicates Behcet's disease, sarcoidosis, or multiple sclerosis. Vasculitis surrounding a localized area of chorioretinal inflammation is, as is well known, characteristic of retinitis due to cytomegalovirus infection, toxoplasmosis and acute retinal necrosis (7). Infiltrates with vasculitis in the absence of infection indicates Behcet's disease (2). Cotton wool spots, typically indicative of arteriolar ischemia, are usually found in association with a systemic vasculitis. Swelling of the optic nerve head, though a common non-specific finding secondary to surrounding vascular inflammation, may indicate infiltrative disease of the optic nerve, as in sarcoidosis.

Vessel Involved	Disease	Retinal features
Medium sized, muscular arteries	Polyarteritis Nodosa	Cotton-wool spots, retinal edema, <u>hypertensive changes</u>
Medium to small arteries	Wegener's granulomatosis	Cotton-wool spots, <u>arteriolar occlusion</u>
Small arteries	Systemic Lupus Erythematosus	Cotton wool spots, hemorrhage, retinal edema, new vessels

Capillaries	Whipple's disease	Hemorrhage, exudates, <u>capillary occlusion</u>
Veins	Behcet's disease	<u>Infiltrates, branch retinal vein occlusion, macular edema, neovascularization</u>
	Sarcoidosis	<u>Periphlebitis, venous sheathing, choroidal granuloma, neovascularization</u>
	Multiple Sclerosis	<u>Venous sheathing, macular edema, neovascularization</u>
Arteries and veins	Crohn's Disease	<u>Vascular Occlusions</u>
	Relapsing Polychondritis	<u>Exudates and hemorrhage</u>

Table 2 Correlation of retinal features of systemic inflammatory disease with size of vessel involved

Fluorescein Angiography

Fluorescein angiography is an essential component of the workup for patients with suspected retinal vasculitis and in many cases may reveal that the vasculitis is more extensive than clinical findings depict (11). It is of particular value in assessing the integrity and density of the retinal pigment epithelium, the permeability and perfusion of retinal vessels, the presence of neovascularization, and the extent of optic disk swelling (7). Arteriolar leakage of fluorescein associated with intraocular inflammation signifies viral or protozoal infection. Systemic vasculitides, on the other hand, usually cause arteriolar occlusion, unassociated with vitreal inflammation. Whipple's disease and syphilis causes leakage from retinal capillaries alone and may give rise to intraretinal hemorrhage and exudates. The most common form of leakage, however, involves the larger venules. Focal venular leakage may indicate sarcoidosis or multiple sclerosis, while diffuse leakage occurs in primary retinal vasculitis and HLA-B27 associated posterior segment disease.

Fluorescein angiography is a diagnostic technique well suited to identify retinal ischemia and has diagnostic and prognostic implications. Peripheral capillary closure is a feature of tuberculosis, sarcoidosis and Eale's disease. Retinal vasculitis with ischemic branch retinal vein occlusion is characteristic of Behcet's disease. Capillary dropout at the fovea is an important sign that is often missed secondary to media opacities or failure to identify the fovea at the appropriate phase of the angiogram and points to a poor visual outcome even after suppression of the disease. Late phase leakage of fluorescein indicates retinal neovascularization, occurring secondary to widespread capillary closure or as a direct consequence of intraocular inflammation.

Finding on fluorescein angiography	Associated Diagnosis
Arteriolar leakage with significant vitritis	Viral/ protozoal infection
Arteriolar occlusion with minimal vitritis	Systemic vasculitis
Capillary leakage with intra- retinal hemorrhage and exudate	Whipple's disease Syphilis
Peripheral capillary closure	Tuberculosis Sarcoidosis Eale's disease
Focal venular leakage	Sarcoidosis Multiple Sclerosis
Diffuse venular leakage	Primary retinal vasculitis HLA B27 associated uveitis

Table 3 Diagnoses associated with fluorescein angiographic findings

Pathogenesis

Vasculitis can be classified into three major pathogenetic categories: infective, immune, and idiopathic (12).

Infectious Vasculitis

Vascular endothelium can be directly invaded by microorganisms such as viruses (parvovirus, HIV, and cytomegalovirus), bacteria (*Rickettsiae*, *Neisseria*, *Streptococcus pneumoniae* and *Staphylococci*) and toxoplasmosis resulting in cellular injury and death. Microorganismal antigenic components may also react with IgG or IgM to form immune complexes, which deposit at the blood vessel wall, activate complement, attract leukocytes, and produce acute inflammation. Larger immune complexes lead to granuloma formation, whereas smaller, more soluble complexes produce an Arthus-type reaction.

Immune Vasculitis

Immune-mediated vasculitis may be either T- cell mediated, as in the vasculitis associated with graft rejection, graft versus host disease and possibly giant cell arteritis and Takayasu's disease. The combination of antigen with antibody and immune complex deposition, however, is thought to be the primary mechanism by which vasculitis occurs in many organs, including the eye.

Preformed immune complexes circulating in the blood may be deposited at the vessel wall, or alternatively, immune complexes may be formed within the vessel wall itself. This occurs if free antigen or antibody occurs outside the vessel wall and corresponding antibody or antigen is in circulation. Such antigens may be heterologous e.g. drugs or microorganismal products, or autologous, as in the connective tissue disorders. Immune complex vasculitis following the ingestion or parenteral use of drugs including sulfonamides, penicillins, non-steroidal anti-inflammatory drugs, anticonvulsants, and propylthiouracil have been shown to cause retinal vasculitis (12). Bacterial, viral and other micro-organismal antigens may also result in immune complex mediated vasculitis, while cryoglobulins found in infections such as hepatitis C and malignancies may also result in vasculitis by a similar mechanism.

Antibodies to proteinase-3 (C- ANCA) cause endothelial damage either directly or through its action on neutrophils; the latter, when activated, release proteolytic enzymes, causing cell injury and death. Vasculitides in this subgroup include Wegener's granulomatosis, Churg-Strauss syndrome, polyarteritis nodosa, and possibly Crohn's disease and some forms of drug induced vasculitis (e.g. propylthiouracil). Antibody against myeloperoxidase, P-ANCA, is characteristic of Churg-Strauss syndrome and microscopic PAN (13). Anti- endothelial cell antibody and anticardiolipin antibodies are also associated with retinal vasculitis, associated with systemic diseases (Behcet's disease, systemic lupus erythematosus), as well as in primary idiopathic retinal vasculitis. Similarly, retinal vasculitis may occur secondary to anti-basement membrane antibodies, as seen in Goodpasture's syndrome.

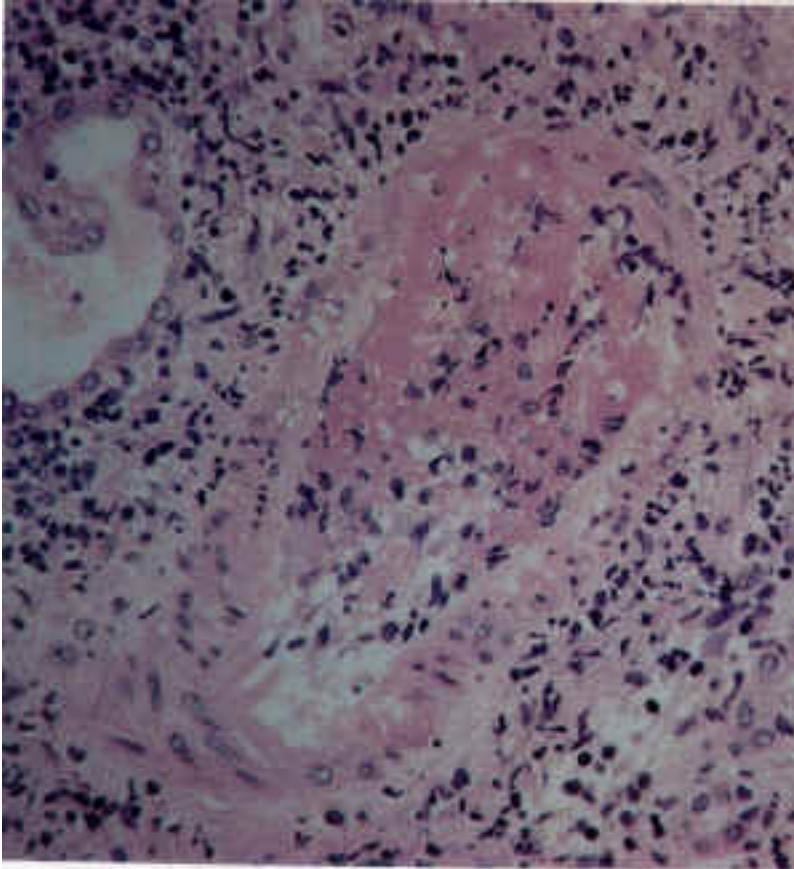


Figure 13 Biopsy specimen from a patient with Polyarteritis nodosa with segmental fibrinoid necrosis and thrombotic occlusion of the arterial lumen

Primary Vasculitis

A number of immunological abnormalities have been associated with primary retinal vasculitis. None, however, have been consistently seen. Lymphopenia, with a normal helper to suppressor T cell ratio (14), increased concentrations of serum immune complexes (16), anticardiolipin antibodies (15), reduced antibody affinity to retinal S antigen (16) and increased expression of IL2- receptor surface markers (17) have been reported in patients with primary retinal vasculitis. The significance of these findings, however, remains to be seen.

Work Up

Patients with retinal vasculitis typically undergo an extensive diagnostic work up. The object of this strenuous search for a definite diagnosis is not solely to satisfy the physician's curiosity. This pursuit is necessary not only to identify associated systemic disease, but also to justify the risks of prolonged immunosuppressive therapy in appropriate cases (11). Discrimination between the infectious or non-infectious etiology of retinal vasculitis is another cornerstone of management. Immunosuppressive therapy may be life saving in systemic vasculitides such as Wegener's granulomatosis, but is an absolute contraindication in infectious etiologies of retinal vasculitis, and a search for systemic disease begins once an infectious etiology is believed unlikely. Minimal testing currently recommended by some comprises a fluorescein angiogram, complete blood count, erythrocyte sedimentation rate, acute phase proteins, protein electrophoresis, blood chemistry and chest radiograph (3,5). Further investigation is tailored according to the patient's symptoms and signs.

Management

Effective management of patients with retinal vasculitis entails a multifaceted approach (9).

Systemic, emotional, and environmental factors may have a significant impact on the course of the disease, and to focus solely on ocular aspects of the condition and its management usually meets with lesser rates of success. Correction of concurrent problems such as dental hygiene, nutritional deficiencies, urinary tract infections, and emotional distress, may be time consuming but are necessary to arrive at a definite diagnosis and evaluate the patient's ability to tolerate some of the therapeutic strategies involved. Patients must develop confidence in the diagnostic and therapeutic programs proposed, and such confidence is generated by a strong physician patient relationship, in which the patient is honestly apprised of his condition, with information presented in a factual manner. This serves to prevent biasing the patient's perception of the problem as well as his or her willingness to accept treatment. An important point to remember is that initial clinical success with anti-inflammatory medications should not distract the physician from an exhaustive diagnostic search for a systemic vascular disease, particularly when ocular or systemic findings may suggest one exists.

Transseptal or subconjunctival steroid injections

These have shown to be extremely effective in treating posterior segment inflammation, and a wide range of drugs is available for periocular injection. Depot preparations are employed only if the patient is not steroid responsive in terms of elevation of intraocular pressure. Transseptal and subconjunctival injections are contraindicated in patients with scleritis, toxoplasmosis and tuberculosis. Retrobulbar injections into the muscle cone are avoided because of the risk of perforation of the globe, a devastating potential complication. Other potential risks include intractable steroid induced glaucoma, orbital granuloma formation with periocular fibrosis and limitation of ocular motility, and adrenal suppression with repeated periocular injection.

Systemic Steroids

High dose systemic steroids are indicated in patients with retinal vasculitis inadequately responsive to periocular steroid injections combined with oral nonsteroidal anti-inflammatory agents. In order to prevent the potential risks of steroid-induced complications in patients on long term systemic therapy, high dose steroids are given for as brief a period as possible to achieve the desired result, with eventual tapering and discontinuation as allowable by the patient's disease course. Relapse of intraocular inflammation usually occurs when tapering is too rapid, and is almost always a mistake. Systemic infection not concomitantly treated with specific antimicrobial therapy, fungal infection, tuberculosis, and uncontrolled diabetes mellitus are contraindications to systemic steroid therapy.

Concomitant use of nonsteroidal anti-inflammatory agents with steroid therapy is thought to be more effective in treating macular edema and may prevent recurrence of ocular inflammation and macular edema when the steroid is withdrawn. Careful monitoring of blood hematocrit and stool for occult blood is mandatory while on such therapy. Side effects include weight gain, irritability, insomnia and hyperkinetic behavior, steroid myopathy, osteoporosis, aseptic necrosis of the hip, Cushing's syndrome, steroid induced diabetes mellitus, aggravation of hypertension, and increased susceptibility to opportunistic infections (4,9).

Oral nonsteroidal anti-inflammatory agents

Oral nonsteroidal anti-inflammatory agents may be effective in eliminating macular edema and in preventing its recurrence, as described above. They are not effective alone; however, in treating retinal vasculitis per se. Possible side effects include gastric distress, dysuria, frequent urination, hematuria, melena, blurred vision, tinnitus, decreased hearing, mental confusion, and toxic hepatitis.

Stress management

It has been seen that stress appears to be a precipitating factor for recurrent intraocular inflammation, and may make the treatment and adequate control of intraocular inflammatory processes more difficult. It is important to emphasize to patients not only the importance of controlling the disease with drugs, but of experiencing less stress (e.g. disease- or job-related) while the acute inflammatory process is being brought under control. In some cases, the care of a psychiatrist or clinical psychologist may be necessary.

Treatment of specific Diseases

Behcet's Disease

Although the vasculitis associated with Behcet's disease responds well to systemic steroids, the

long-term consequences of these drugs in this chronic disease are unacceptable. In addition, it appears that systemic steroid therapy delays the time to blindness in patients with posterior segment involvement, but does not alter the long-term outcome (18). Mild to moderate Behcet's syndrome with no posterior segment involvement may be adequately treated with Colchicine while more severe or recalcitrant cases, and patients with posterior segment involvement, require Cyclophosphamide, which is thought to be the most effective therapy to date. This drug is used in any Behcet's syndrome patient with posterior segment involvement and in patients in whom therapeutic control with Colchicine is failing. Monitoring and adjustment of dosage must, however, be by an expert in the use of cytotoxic drugs. Complications may be substantial and include excessive bone marrow suppression, hemorrhagic cystitis, and eventual bladder fibrosis or carcinoma, interstitial pneumonitis, toxic hepatitis, hemorrhagic colitis, oral mucosal ulceration, alopecia, and gonadal suppression. Chlorambucil is also effective, but at the dose required to control the disease, the systemic complication rate with Chlorambucil is considerably higher than that with Cyclophosphamide (9). Cyclosporin may also be effective treatment in some patients with Behcet's syndrome, but cost has restricted its use to the treatment of patients who do not tolerate Cyclophosphamide and in those who definitely plan future pregnancies. Toxicity includes an apparent increase in the incidence of B-cell lymphomas, interstitial pneumonitis, and renal tubule toxicity.

Polyarteritis Nodosa

This systemic necrotizing vasculitis is usually fatal if not treated with immunosuppressive agents. In untreated patients, the 5-year survival rate is approximately 13%, but has been reported to be 53% in patients treated with a combination of corticosteroids and a cytotoxic agent (2). The most effective agent in treating these patients is Cyclophosphamide. If given orally, patients are instructed to limit intake to the morning and to encourage substantial fluid intake throughout the afternoon and evening. Therapy is maintained for a minimum of 1 year.

Systemic Lupus Erythematosus

Oral nonsteroidal anti-inflammatory agents and Chloroquine may be the only agents required to control arthralgias, arthritis, and cutaneous lesions in mild cases of SLE. More severe cases require daily systemic corticosteroid or cytotoxic therapy, again, such as Cyclophosphamide. Lupus crisis may require plasmapheresis, and ocular manifestations resolve once the underlying systemic disease activity is controlled.

Sarcoidosis

Topical, transseptal and oral steroids appear to be the mainstay in the treatment of patients with the ocular complications of sarcoidosis, and a process of trial and error discovers the lowest possible dose required to control the disease. Once that dose is discovered, the patient is maintained on that dose indefinitely, since it has been seen that repeated attempts at withdrawal result in multiple disease remissions and exacerbations and significant physical and emotional debilitation. Cyclosporin A, Methotrexate and Chlorambucil also have therapeutic effects in patients with sarcoidosis, and in some cases may be used in combination with systemic steroids (2).

Laser and Surgical Treatment

Panretinal photocoagulation is indicated in patients with widespread ischemic retinal vasculitis who have recurrent vitreous hemorrhages. Grid laser photocoagulation may be considered in patients with chronic macular edema arising from retinal vasculitis, and although this induces some resolution of the edema, visual improvement does not necessarily occur (4). Vitrectomy is of benefit to clear the media when there is marked inflammatory debris and hemorrhage and to remove epiretinal membranes.

Prognosis

It is difficult to be precise about eventual visual outcome in patients with retinal vasculitis when the course of the disease may be so varied. In idiopathic, nonischemic disease, outcome is considered by some to be good, better than 20/200 in up to 95% after a mean follow up of 8 years. In ischemic retinal vasculitis, however, this is reduced to 67%, usually as a result of

irreversible macular changes or branch retinal vein occlusion (4). Interestingly, relapse rate does not appear to be an important factor in determining visual outcome, and has been found to be the same in both varieties of the disease (19).

Systemic disease may become apparent after prolonged follow-up in patients with retinal vasculitis, and seems to relate to the initial findings on fluorescein angiography. Up to 30% of patients with ischemic disease, particularly young women, may develop clinically definite multiple sclerosis within 6 years of presentation. In the same period, 33% of ischemic retinal vasculitis patients (non Eale's) will develop life-threatening thrombosis (myocardial infarction or stroke) (4). In this group, urgent correction of potential risk factors (smoking, hypertension, hyperlipidemia) is needed, as the mean age at presentation in these patients is frequently younger than 30 years.

Conclusion

Retinal vasculitis can be an insidious, sight threatening condition that has pathognomic clinical features identifiable on clinical examination. A thorough diagnostic work up directed by the patient's symptoms and signs is a mandatory in this disease. A number of systemic associations occur with retinal vasculitis, and it is the responsibility of the ophthalmologist to help direct such a search, particularly in cases where systemic findings are scarce. Once an infectious etiology is ruled out and a systemic vasculitis identified, immunosuppressive therapy is usually required to induce lasting control of both ocular and systemic disease.

References

1. Holland GN. Retinal vasculitis. *West J Med* 1991;154:218-220
2. Nussenblat RB, Whitcup SM, Palestine AG. Retinal vasculitis. In: *Uveitis, Fundamentals and Clinical Practice*, 2nd ed. St Louis: Mosby, 1996;354-363
3. Rosenbaum JT, Robertson JE, Watzke RC. Retinal vasculitis- a primer. *West J Med* 1991;154:182-185
4. Stanford MR, Verity DH. Diagnostic and therapeutic approach to patients with retinal vasculitis. *Int Ophthalmol Clin* 2000;40:69-83
5. Abu El-Asrar AM, Tabbara KF. Retinal vasculitis. *Curr Opin Ophthalmol* 1997;8:68-79
6. Sanders MD, Graham EM. Retinal vasculitis. *Postgrad Med J* 1998;64:488-496
7. Stanford MR, Graham EM. Systemic associations of retinal vasculitis. *Int Ophthalmol Clin* 1991 31:23-33
8. Opremac EM. Collagen disorders: Retinal manifestations of collagen vascular diseases. In: Albert DM, Jakobiec FA eds. *Principles and Practice of Ophthalmology*, 2nd ed. Saunders, 2000;2176-2185
9. Foster CS, Regan CD. Retinal vascular diseases: Management. *Int Ophthalmol Clin* 1986;26:55-71
10. Mandell BF, Hoffman GS. Differentiating the vasculitides. *Rheum Dis Clin N Am* 1994;20:409-441
11. Regan CD, Foster CS. Retinal vascular diseases: Clinical presentation and diagnosis. *Int Ophthalmol Clin* 1986;26:25-53
12. Rahi AH, Tabbara KF. Retinal vasculitis: Pathogenesis and laboratory investigations. *Int Ophthalmol Clin* 1995;35:93-105
13. Hellman DB, Stone JH. Arthritis and musculoskeletal disorders. In Tierney LM, McPhee SJ, Papadakis MA, eds. *Current Medical Diagnosis & Treatment*, 40th ed. Lange, 2001;814-868
14. Wakefield D, Easter J, Penny R. Immunological abnormalities in patients with untreated retinal vasculitis. *Br J Ophthalmol* 1986;70:260-265
15. Klok A, Geertzen R, Rothova A, Baarsma GS, Kijlstra A. Anticardiolipin antibodies in uveitis. *Curr Eye Res* 1992; suppl. 11:209-213
16. Kasp E, Whitson R, Dumonde D, et al. Antibody affinity to retinal S-antigen in patients with retinal vasculitis. *Am J Ophthalmol* 113:697-701
17. Dick AD, Cheng YF, Purdie AT, Liversidge, JV, Forrester JV. Immunocytochemical analysis of blood lymphocytes in uveitis. *Eye* 1992;6:643-647

18. Jabs DA, Rosenbaum JT, Foster CS et al. Guidelines for the use of immunosuppressive drugs in patients with ocular inflammatory disorders: Recommendations of an expert panel. Am J Ophthalmol 2000;130:492-513
19. Palmer HE, Stanford MR, Sanders MD, Graham EM. Visual outcome of patients with idiopathic ischemic and non-ischemic retinal vasculitis. Eye 1996;10:343-348

Retinal Vasculitis

Khayyam Durrani, M.D.

1. Most systemic vasculitides causing retinal vasculitis are thought to occur by
 - a) direct invasion by microorganisms
 - b) anti-endothelial cell antibodies
 - c) immune complex deposition
 - d) anti-basement membrane antibodies
 - e) anticardiolipin antibodies
2. Vasculitis involving the retinal arterioles may indicate which of the following
 - a) Wegener's granulomatosis
 - b) Multiple Sclerosis
 - c) Crohn's disease
 - d) Polyarteritis Nodosa
 - e) Whipple's disease
3. Visual prognosis in retinal vasculitis is correlated with
 - a) gender
 - b) relapse rate
 - c) retinal ischemia
 - d) all of the above
 - e) none of the above
4. C- ANCA is associated with which of the following
 - a) Polyarteritis Nodosa

- b) Churg-Strauss syndrome
- c) Wegener's granulomatosis
- d) Takayasu's arteritis
- e) Crohn's disease

5. Which of the following is not a presenting feature of retinal vasculitis unassociated with systemic disease

- a) Photopsia
- b) Floaters
- c) Ocular discomfort
- d) Blurred vision
- e) Visual field defects

6) Patients with retinal vasculitis with evidence of ischemia on fluorescein angiography are at an increased risk of which of the following

- a) multiple sclerosis
- b) myocardial infarction
- c) poor visual prognosis
- d) stroke
- e) all of the above

7) A fluorescein angiogram is always required in the work up of patients with retinal vasculitis T/F

8) Polyarteritis nodosa is best treated with oral steroids and a cytotoxic agent T/F

9) Capillary leakage on fluorescein angiography is indicative of

- a) Multiple Sclerosis
- b) Whipple's disease
- c) Wegener's granulomatosis
- d) Syphilis
- e) None of the above

10) Patients with Behcet's disease with posterior segment involvement must be treated with

a) Colchicine

b) Topical steroids coupled with transseptal steroids

c) Immunosuppressives other than steroids

d) Systemic steroids alone

e) Systemic steroids with an oral non steroidal anti-inflammatory agent

Answers: 1)C 2)A,C,D 3)C 4)A,B,C,E 5)C 6)E 7)T 8)T 9)B,D 10)C