

# Serpiginous Choroiditis

Andrea P. Da Mata, M.D.

## ABSTRACT

**Background:** Serpiginous choroiditis also called geographic helicoid peripapillary choroidopathy is a rare, idiopathic inflammatory disease affecting the inner choroid and retinal pigment epithelium. Typically serpiginous choroiditis occurs bilaterally and is relentlessly progressive. Though long standing remissions can be achieved through aggressive immuno-modulation, patients not receiving such therapy often suffer through multiple exacerbations and are often left with macular scarring, and significant visual loss.

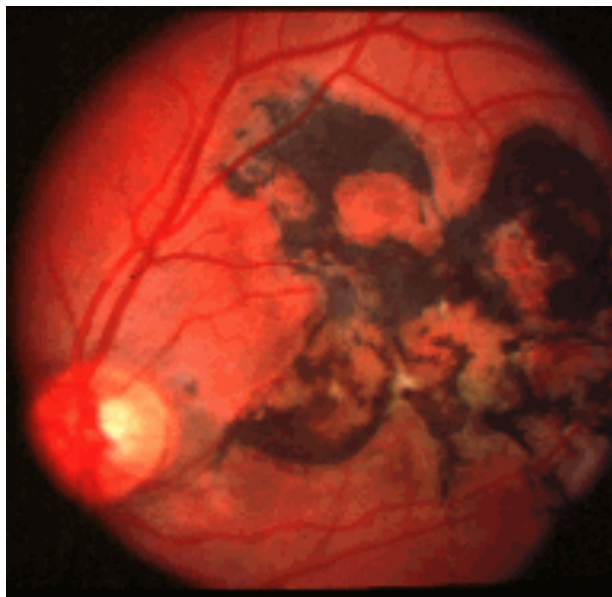
**Materials and Methods:** A 28 year-old man presented with 2 weeks of blurry vision in his right eye, and long standing decreased vision in his left eye. He noted worsening of his vision OD despite prior treatment with oral and topical corticosteroids.

**Results:** A diagnosis of serpiginous choroiditis was made. The patient was treated with triple agent immunosuppressive therapy and enjoyed dramatic improvement in his visual acuity in both eyes. Over the past 3 years his disease has remained quiescent while the immunosuppression is being slowly weaned.

**Conclusion:** Serpiginous choroiditis is a rare idiopathic inflammatory disease. The diagnosis of serpiginous choroiditis is made based upon its clinical manifestations. Treatment of serpiginous choroiditis requires aggressive immunosuppression and careful, long-term observation.

## Case Report

A 28 year-old Italian man from Milano was referred with a 2 week history of blurred vision in his right eye that was getting progressively worse despite treatment with systemic and topical corticosteroids. His past ocular history was significant for idiopathic macular chorioretinitis in the left eye 8 years earlier. He noted a recent flu like illness. He denied any family history of ocular disease.



**Fig. 1** \_\_\_\_\_ **Fig. 2**

Examination demonstrated a visual acuity of 20/30 OD, and 20/200 OS. Anterior segments were quiet OU. Intraocular pressures were 13 mm Hg in both eyes. The funduscopy exam of the right eye revealed a parafoveal, subretinal, elevated, grayish-yellow lesion and a gray subretinal lesion in the infero-nasal macula (**Figure 1**). Funduscopy exam of the left eye demonstrated a large geographic pigmented chorioretinal scar throughout the macula (**Figure 2**).

Fluorescein angiography showed early hypofluorescence followed by late leakage in the active areas of the right eye (Figures 3 & 4). The old lesion in the left eye demonstrated blockage of fluorescence corresponding to the areas of RPE hypertrophy with staining along the edges (**Figure 5**).

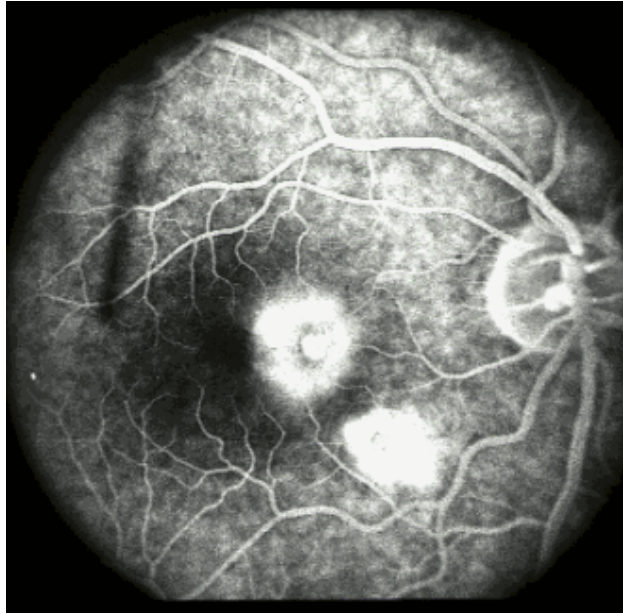
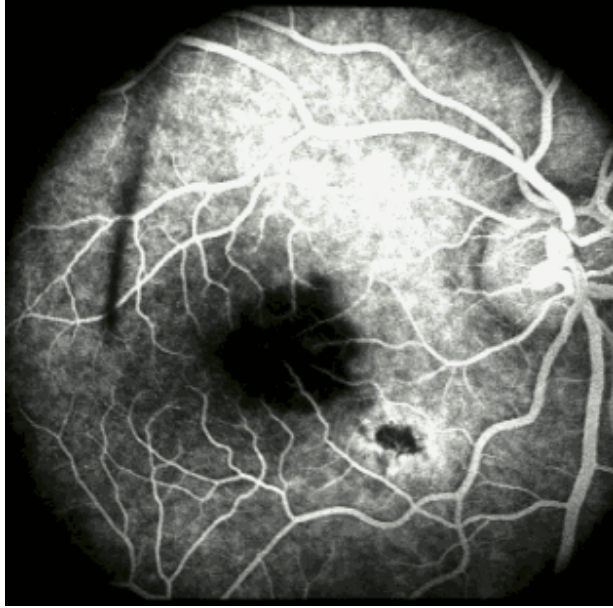
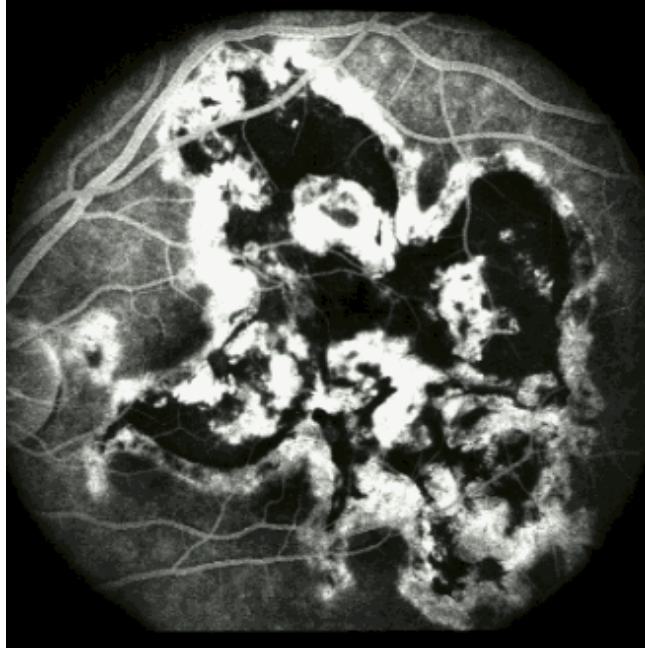
Fig. 3 \_\_\_\_\_ Fig. 4



**Fig. 5**

An extensive work up was undertaken including: CBC, ESR, ACE, RPR, FTA/ABS, HIV, Hepatitis B, Hepatitis C; HSV, CMV, toxoplasma, and Lyme titer, as well as a urinalysis and chest X ray, and all of these tests were normal. He had a positive hepatitis A IgG and herpes zoster virus IgG which were believed to be unrelated to his current problem.

Based on the clinical presentation, fluorescein angiography, and negative work up for systemic or infectious disease a diagnosis of serpinginous choroiditis was made. Treatment with cyclosporin 200 mg po daily and prednisone 60 mg po daily was initiated.

**Fig. 6**

The patient returned 1 week later complaining of worsening of his vision. His visual acuity was 20/200 OD, 20/300 OS. The anterior segments remained normal, but the fundus of the right eye showed increased subretinal fluid and continued active choroiditis (**Figure 6**). Facing this situation we increased the cyclosporin to 300 mg daily, and added azathioprine 150 mg daily. The prednisone was continued at 60 mg daily.

Fig. 7

One week later (2 weeks after the initial presentation) he returned with a visual acuity of 20/50 OD, 20/70 OS. Dilated funduscopic exam of the right eye showed a healing lesion with increasing pigmentation and a salt and pepper appearance (Figure 7). Funduscopic exam of the left eye appeared unchanged despite the significant improvement in vision. At this point the cyclosporin and azathioprine were continued, and the prednisone was reduced to 40 mg daily.

4 weeks after the initial presentation he came back complaining of a scotoma in his right eye. His visual acuity was 20/30 OD, 20/70 OS and a pigmented glistening scar could be seen on fundus examination OD (Figure 8). The cyclosporin was increased to 400 mg daily approaching the goal of 500 mg daily.

Fig. 8 \_\_\_\_\_ Fig. 9

6 weeks after the initial visit he returned with a visual acuity of 20/16 OD, 20/63 OS. The fundus exam showed a geographic inactive pigmented chorioretinal scar (Figure 9). The cyclosporin was increased to 500 mg daily, and azathioprine was increased to 200 mg daily, prednisone was continued at 40 mg daily.

The patient returned to Italy with this maintenance treatment. During the past 3 years his immunosuppressive therapy has been tapered to 150 mg daily of cyclosporin, 150 mg daily of azathioprine, and 10 mg of prednisone every other day. He is monitored with periodic blood pressure measurements, and labs including: CBC, BUN, creatinine. He is being carefully followed in collaboration with his local ophthalmologist by serial photos with FA/ICG. His eyes are doing extremely well. He currently enjoys visual acuities of 20/16 OD and 20/60 OS. There has been no sign of reactivation to date.

## SERPIGINOUS CHOROIDITIS

Serpiginous choroiditis also called geographic helicoid peripapillary choroidopathy is a rare idiopathic inflammatory disease affecting the inner choroid and retinal pigment epithelium.

### **Epidemiology**

Serpiginous choroiditis is slightly more common in men. The age of the onset usually ranges from 30 to 70 years, although it may occur in younger patients. There is no proven racial predilection, no familial propensity and no known associations with drugs, trauma or allergy. The condition appears to have no related systemic manifestations. Erkkila and colleagues reported in a Finnish study an association of serpiginous choroiditis with a greater prevalence of HLA B7. King and associates described an elevated factor VIII-vWF in 8 patients, and Broekhuysse and coworkers demonstrated increased immune responsiveness to retinal S antigen (arrestin) in patients with serpiginous choroiditis.

### **Presentation**

Patients with serpiginous choroiditis can present variable vision that ranges from normal to hand movements. Visual field examination typically will reveal small central or paracentral scotomas. The anterior segment is usually normal, however, anterior uveitis and vitritis may occur. The optic nerve is not affected. The electroculogram and electroretinogram tend to be unchanged, although extensive disease does cause abnormal results.

### **Histopathology**

The histopathology of serpiginous choroiditis is not extensively documented. Wu et al. reported the pathologic findings in a patient with the clinical features of serpiginous choroiditis. They noted diffuse and focal lymphocytic infiltrates in the choroid. The infiltrate was greatest at the margins of the lesions. Atrophy of the overlying RPE and photoreceptors was seen. There was a variable degree of RPE hyperplasia. Breaks in Bruch's membrane were also seen, with fibroglial tissue proliferating through.

### **Chorioretinal Findings**

The typical lesion is discoid or geographic in shape often with finger-like projections. Lesions generally begin in the peripapillary area, but the macula, regrettably, may be the initial site of involvement. Acute lesions appear grayish-yellow with distinct borders. As the lesions heal there is chorioretinal scarring with variable RPE hypertrophy, and atrophy, as well as fibrosis. Choroidal neovascularization occurs in about 25% of the patients, and may lead to subretinal fluid and hemorrhage. Other findings may include retinal vasculitis, retinal detachment, RPE detachment, branch vein or combined branch vein-artery occlusion and neovascularization of the optic disc or elsewhere.

### **Clinical Course**

Serpiginous choroiditis is a chronic, bilateral, asymmetric, and progressive disease. Acute lesions last weeks to months then resolve with scarring and atrophy. Recurrence is the rule. The new lesions spread centrifugally contiguous to previous scars. Untreated, the prognosis is generally poor, though extent of visual loss is often unpredictable.

### **Diagnosis**

The diagnosis of serpiginous choroiditis is based on clinical findings. The fluorescein angiography is quite helpful. During the early phases the acute lesions are hypofluorescent due to blockage by edematous RPE and choroidal non-perfusion. The late phase of the angiogram demonstrates leakage and staining in the active areas. Old chorioretinal scars have a mottled appearance caused by pigment clumping and atrophy, with late staining on fluorescein angiography.

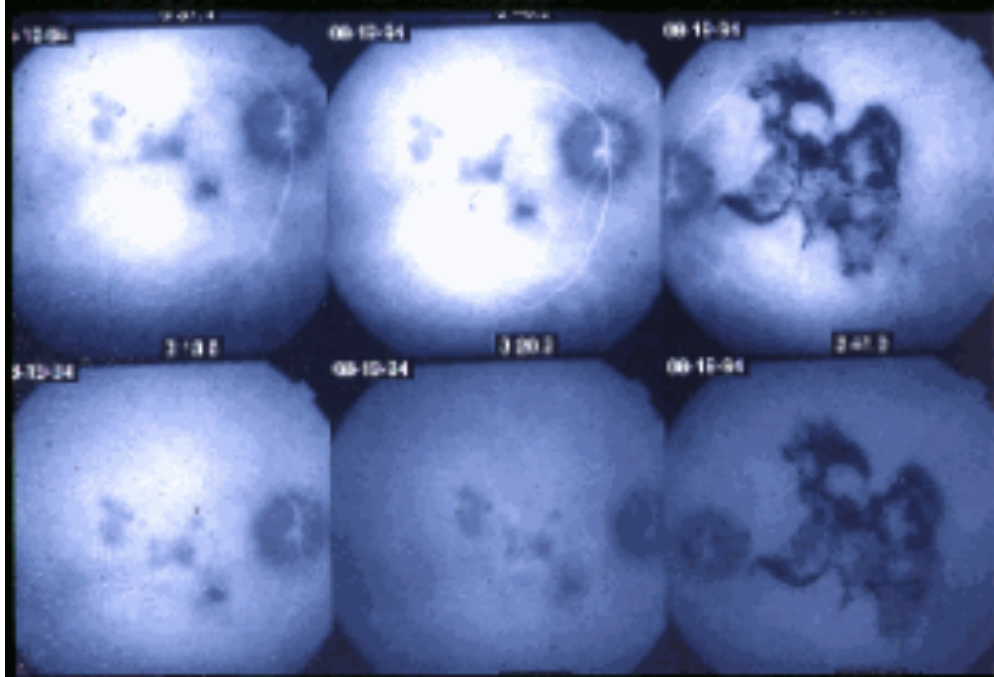


Fig. 10

Indocyanine Green angiography is useful for identification and staging of new active lesions. The area of choroidal nonperfusion seen by ICG during the acute stage is generally larger than the corresponding clinically observed retinal lesions. (**Figure 10**) The ICG is also useful in detecting subclinical or persistent choroidal nonperfusion even when the signs of retinal activity have disappeared.

Differential

#### **Diagnosis:**

The most important condition to consider in the differential diagnosis of serpiginous choroiditis is acute posterior multifocal placoid pigment epitheliopathy (APMPPE). APMPPE lesions affect the choroid and RPE, resulting in a fundus appearance and fluorescein angiographic pattern that may be indistinguishable from serpiginous choroiditis. However there are several clinical characteristics of APMPPE that allow one to differentiate it from serpiginous choroiditis. APMPPE patients are generally younger with simultaneous bilateral involvement. The lesions heal in 7 to 14 days and recurrences are rare. Residual scarring is generally limited to minimal choroidal atrophy, and the visual outcome in APMPPE tends to be much better than serpiginous choroiditis. Patients with APMPPE also often note a preceding viral illness.

Other diseases that should be included in the differential diagnosis are toxoplasmosis, TB, syphilis, sympathetic ophthalmia, sarcoidosis, multifocal choroiditis, histoplasmosis, ARMD,



posterior scleritis, angioid streaks, choroidal tumors or any condition that causes either choroidal ischemia or peripapillary subretinal neovascularization with scarring.

## TREATMENT

Serpiginous choroiditis has tended to be progressive despite corticosteroid therapy. Yet, oral or trans-septal corticosteroid has been the standard therapy for active disease. Steroid sparing therapy was first suggested by Hooper and Kaplan, with combination azathioprine, cyclosporine and prednisone. Many experienced observers, including our service, believe that this triple therapy or other immunosuppressive regimen (e.g. cyclophosphamide) may shorten the duration of the acute lesions and prevent recurrences.

CNVM may be treated with laser photocoagulation for extrafoveal and juxtafoveal lesions. Subfoveal CNVM lesions have a poor prognosis, but experimental therapies such as photodynamic therapy or proton beam irradiation may prove helpful in the future.

### Follow Up

Patients must be followed carefully. A prolonged course of immunosuppression is given with a very slow taper to avoid recurrence. Amsler grid is very useful to monitor the course and activity of the disease, because the scotomas correspond with the choroidal lesions. Serial photos with FA/ ICG are also helpful in monitoring disease activity.

---

## References:

Bock C, Jampol LM: Serpiginous Choroiditis *In* Albert DM, and Jakobiec FA, (ed): Principles and Practice of Ophthalmology, WB Saunders Philadelphia 1994, pp 517-523.

Broekhuysse RM, Van Herck M, Pinckers AJLG, et al: Immune Responsiveness to Retinal S-Antigen and Opsin in Serpiginous Choroiditis and Other Retinal Diseases. *Doc Ophthalmol* . 1988; 69:83-93

Erkkila H, Laatikainen L, Jokinen E: Immunological Studies on Serpiginous Choroiditis. *Graefe's Arch Clin Exp Ophthalmol*. 1982; 219:131-134

Giovannini A, Mariotti C, Ripa E, et al: Indocyanine Green Angiographic Findings in Serpiginous Choroidopathy. *Br J Ophthalmol*. 1996; 80:536-540

Giovannini A, Ripa E, Scassellati-Sforzolini B, et al: Indocyanine Green Angiography in Serpiginous Choroidopathy. *Eur J Ophthalmol*. 1996; 3:299-306

Hardy RA, Schatz H: Macular Geographic Helicoid Choroidopathy. *Arch Ophthalmol*. 1987; 105:1237-1242

Hooper PL, Kaplan HJ: Triple Agent Immunosuppression in Geographic Helicoid Choroidopathy. *Ophthalmology*. 1991; 98:944-952

Jampol LM, Orth D, Daily MJ, Rabb MF: Subretinal Neovascularization with (Geographic)Serpiginous Choroiditis. *Am J Ophthalmol*1979; 88:683

King DG, Grizzard WS, Sever RJ, Espinosa L: Serpiginous Choroidopathy Associated with Elevated Factor VIII-von Willebrand Factor Antigen. *Retina* 1990; 10:97.

Mansour AM, Jampol LM, Packo KH, Hirsomalos NF: Macular Serpiginous Choroiditis. *Retina*. 1988; 8:125-131.

Schatz H, McDonald HR, Johnson RN: Geographic Helicoid Peripapillary Choroidopathy (Serpiginous Choroiditis) *In* Ryan SJ, (ed): *Retina* 2<sup>nd</sup> Edition, Mosby St. Louis 1994, pp1721-1728

Wu JS, Lewis H, Fine SL, et al: Clinicopathologic Findings in a Patient with Serpiginous Choroiditis and treated Choroidal Neovascularization. *Retina*. 1989; 9:292

## **Review Questions for Serpiginous Choroiditis**

**Andrea P. Da Mata, M.D.**

1. Serpiginous choroiditis presents with all of the following EXCEPT:
  - a. little to moderate vitritis
  - b. blurred vision
  - c. optic neuritis
  - d. central or paracentral scotomas
  
2. Serpiginous choroiditis:
  - a. is bilateral and symmetric
  - b. is more common in whites
  - c. is more common in the first and second decades of life
  - d. may recur after several months to years
  
3. The chorioretinal lesions:
  - a. usually start in the macula
  - b. frequently develop a macular star with subretinal edema
  - c. spread outward in a contiguous pattern
  - d. have telangiectatic vessels and intraretinal hemorrhages around the lesions
  
4. Which of the following diseases may be considered in the serpiginous choroiditis differential diagnosis:
  - a. Sarcoidosis
  - b. APMPE
  - c. Toxoplasmosis
  - d. Angioid streaks
  - e. All of the above
  
5. Serpiginous choroiditis exhibits:
  - a. Non Mendelian inheritance
  - b. Autosomal recessive inheritance
  - c. No genetic propensity

d. X-linked recessive inheritance

6. Wu and colleagues reported the clinicopathologic findings of serpiginous choroiditis. All of the following are true EXCEPT:

- a. They noted diffuse and focal lymphocytic infiltrates in the choroid.
- b. Atrophy of the overlying RPE and photoreceptors was seen.
- c. There was a variable degree of RPE hyperplasia.
- d. Bruch's membrane remained free of breaks.

7. All of the following are true statements about serpiginous choroiditis EXCEPT:

- a. Amsler grid is very helpful to monitor the course and activity of the disease .
- b. The patients must be followed carefully.
- c. Visual prognosis has generally been poor.
- d. FA and ICG have no use for diagnosis or follow up.

8. Immunosuppressive therapy:

- a. stops the progression immediately.
- b. should never be used.
- c. has been reported, in uncontrolled series, to be superior to steroid therapy for treatment of serpiginous choroiditis.
- d. should be used no longer than 6 months.

9. All of the following are complications of serpiginous choroiditis EXCEPT

- a. retinal vasculitis
- b. cataract
- c. CNVM
- d. retinal detachment

10. The clinical course of serpiginous choroiditis is typically:

- a. chronic and progressive
- b. a single acute episode
- c. benign with no permanent scarring
- d. self-limited

Answers:

1.c 6.d

2.d 7.d

3.c 8.c

4.e 9.b

5.c 10.a

