

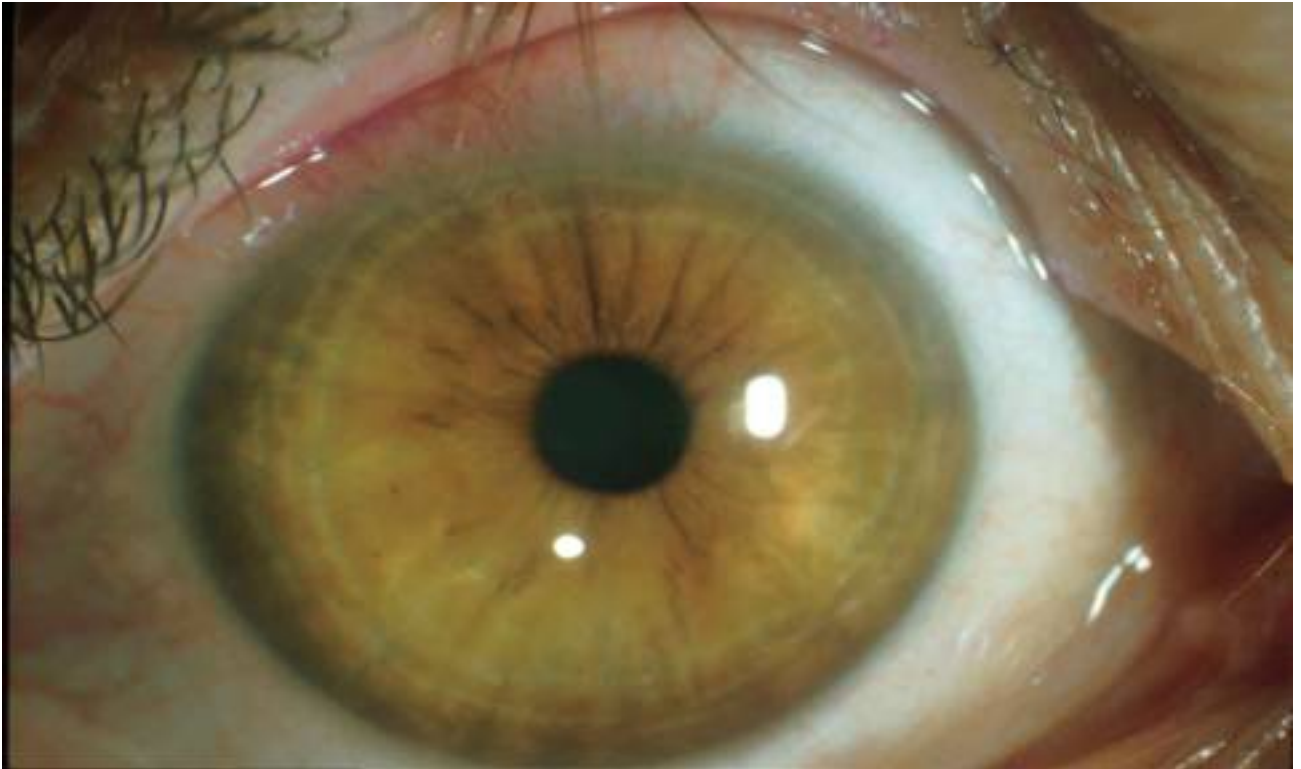## Superior Limbic Keratoconjunctivitis

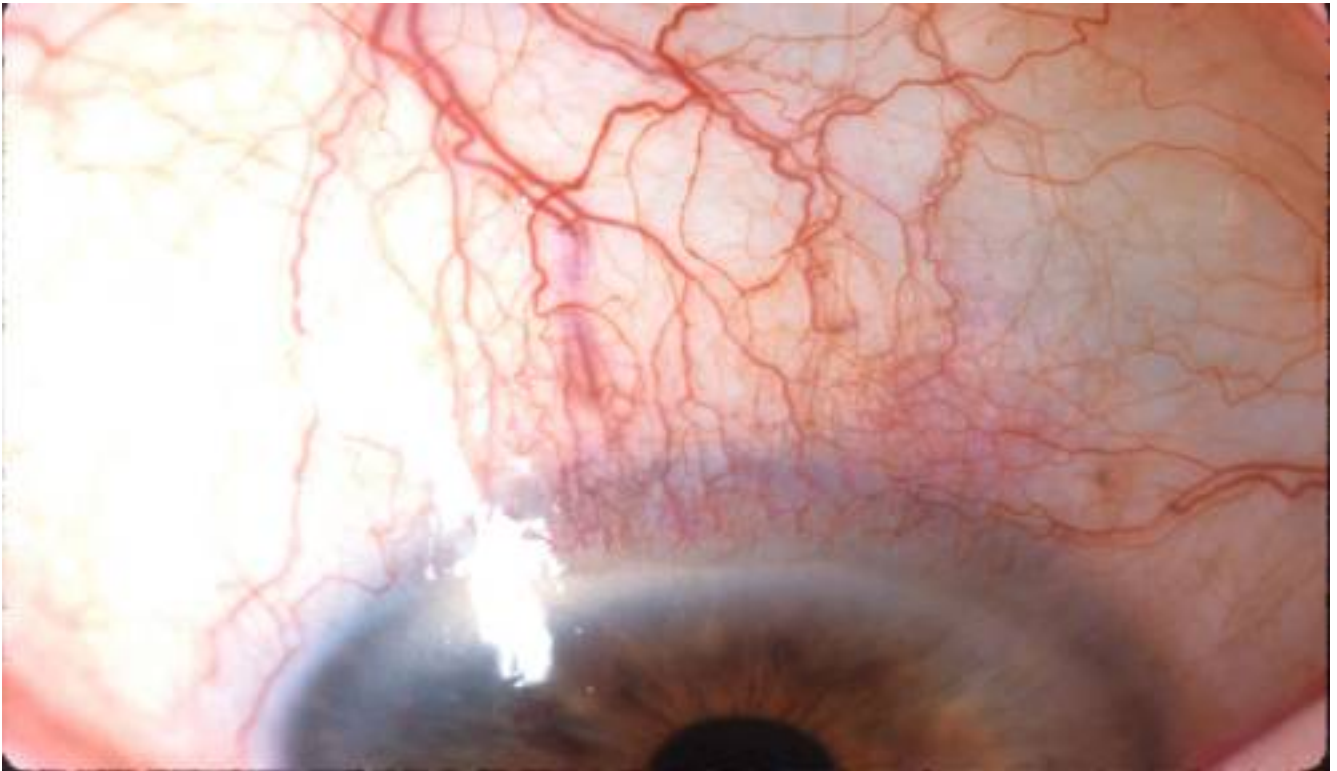
George N. Papaliodis, MD

### Case Presentation:

OW is a 56 yo female with past medical history of hypertension who presented complaining about chronic irritation OU for the preceding 3 years. She had been examined by referring ophthalmologists with diagnoses including conjunctivitis, dry eyes, seasonal allergies, and meibomian gland dysfunction. Prior therapeutic strategies which had largely been unsuccessful included artificial tears, acular, tobradex, doxycycline, tetracycline, erythromycin. The only treatment which offered temporary relief included bandage contact lens.

On examination, the patient had 20/15 Va OU with normal intraocular pressures. Her slit lamp examination was as follows:





The appearance of the above conjunctiva was consistent with a diagnosis of superior limbic keratoconjunctivitis. Rose bengal application revealed punctate staining over the involved region. Thyroid functions tests were performed at the primary care doctor's office and were within normal limits. The patient underwent conjunctival resection with pathology revealing a large section of conjunctiva devoid of inflammatory cells. Her symptoms completely resolved after the procedure.

#### Superior Limbic Keratoconjunctivitis

Superior limbic keratoconjunctivitis (SLK) was first described in detail as a clinical entity by Dr. Frederick Theodore in 1963 although Dr. Thygeson had commented on certain manifestations earlier. In Theodore's description, he depicted patients who presented complaining about the insidious onset of burning and irritation often with abrupt resolution.

SLK is a chronic recurrent condition of ocular irritation and injection more commonly found in women ages 20-70. The signs and symptoms develop slowly over 1 to 10 years. The most common symptoms include foreign body sensation, burning, pain, photophobia, and blepharospasm. The most common signs include injection of superior bulbar conjunctiva, fine papillae on superior tarsal conjunctiva, thickening of superior bulbar conjunctiva, hypertrophy of superior limbus, aqueous tear deficiency, and corneal filaments. The condition is usually bilateral, and vision is usually unaffected. The diagnosis is made by clinical presentation. Rose bengal staining typically reveals punctate uptake of the stain over the region of involved conjunctiva.

#### **Pathogenesis**

The pathogenesis of this condition is unclear. The most plausible explanation is SLK causes edema of the superior bulbar conjunctiva (from unclear etiology) which results in increased friction between superior eyelid and globe.

Conditions associated with SLK include: thyroid abnormalities (usually hyperthyroidism), contact lens wear, graft versus host disease, and preservatives from ophthalmologic medications. Presumably the aforementioned entities can induce edema of the superior bulbar conjunctiva and produce the manifestations as noted.

Pathologic specimens usually show keratinization of the conjunctiva, loss of goblet cells, and acanthosis.

### **Treatment**

The most commonly utilized effective therapy for SLK is a large diameter contact lens wear (encompassing the entire region of pathology). Surgical measures are curative and include conjunctival resection of the superior limbal conjunctiva and thermal cautery of superior limbal conjunctiva.

## **Superior Limbic Keratoconjunctivitis**

**George Papaliadis, M.D.**

1. SLK is associated with which of the following conditions:
  - a. hyperthyroidism
  - b. graft versus host disease
  - c. contact lens wear
  - d. all of the above
2. Curative treatment for SLK includes:
  - a. contact lens wear
  - b. artificial tears
  - c. resection of the superior tarsal conjunctiva
  - d. topical vitamin A
3. T/F The diagnosis is usually made by pathologic specimen.
4. T/F Visual acuity is significantly impaired by SLK.
5. T/F Women are affected more commonly than men.

Answer Key

1d 2c 3F 4F 5T