

# Case conference

Kittikamol Vongpaisarnsin, MD

November, 30 2012

**48 year old female, Hispanic** (first visit - October 25, 2012)

CC: sudden loss of vision OU 2 weeks ago

PI: - 1 month ago - noted difficulty with vision, trouble focusing on computer

- 9 days ago – gradually worsened, no longer read, saw a black shadow with distorted central vision OU

- 6 days ago (10/19/12) - went to see a retinal specialist

- FA, OCT test, serologies investigation

- on pred forte 4 times daily OD

- associated headache and eye pain -> CT scan showed no abnormalities

## ■ Ocular history

- No trauma
- No history of eye surgery

## ■ Past medical history

- Migraines
- Osteopenia
- Arthritis

## ■ Family history

- no family history of RD, retinal degeneration, or glaucoma

## ■ Medication

- Sumatriptan (100 mg)
- Nortriptyline Hcl (25 mg)

## ■ Sulfa allergy

## ■ Social history

- owned a dog, never owned a cat
- Occasionally alcohol use
- Tobacco use 1 pack/ week

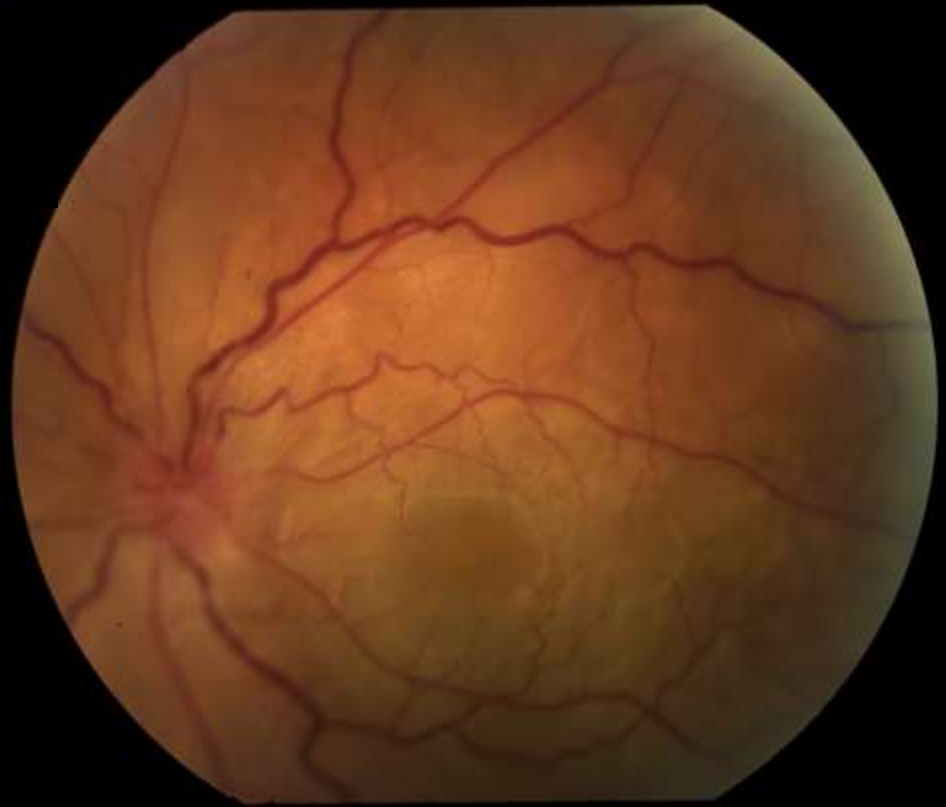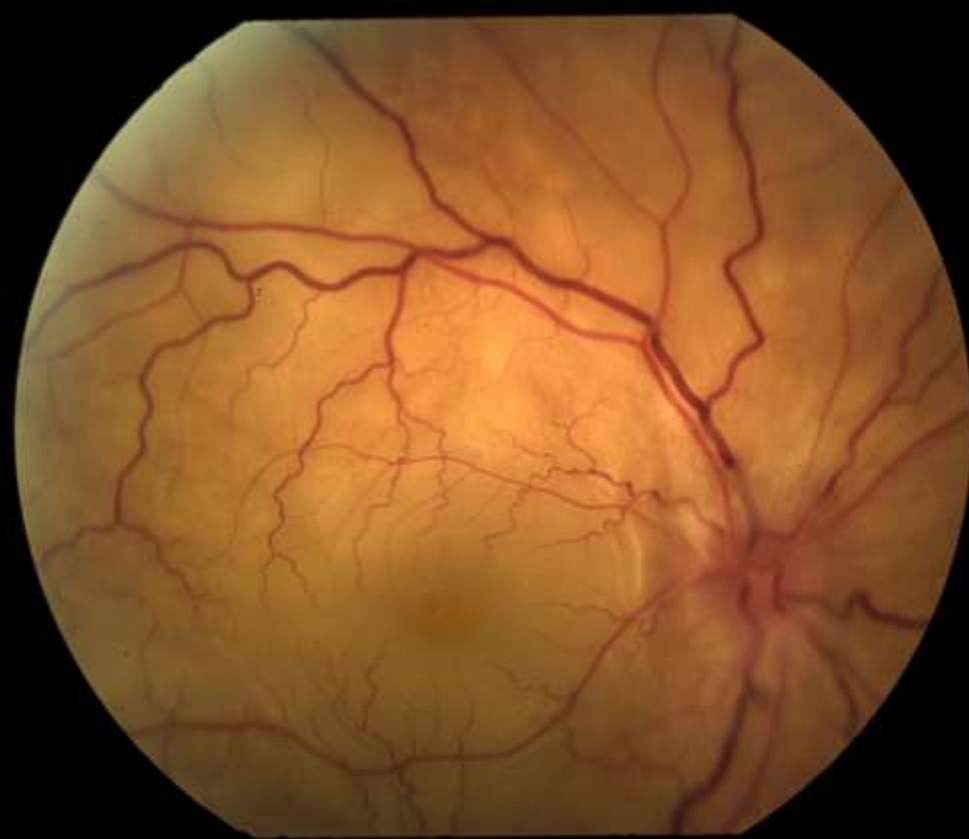
## ■ Review of systems

- Frequent headaches
- Malaise, fatigue
- Poor Appetite, unexplained Weight Loss
- Ringing or noises in ears
- Feels tightness in her fingers
- Reports weakness of knees last week
- Denies hearing loss or any skin lesions or whitening of hair

# Ocular examination

- VA: OD FC 3 ft ph same, OS 20/150 ph same
- IOP: 15, 16 mmHg.
- Eyelids: normal , subtle poliosis OU
- Anterior segment
  - Conjunctiva: normal OU
  - Cornea: clear and compact OU
  - Anterior Chamber: OD 1+ cell OS 1.5+ cell
  - Iris: normal OU
  - Lens: clear OU

- Fundus: clear vitreous OU



# Problem lists

- Sudden visual loss with serous retinal detachment OU
  - Associated with headache, malaise and weakness of the legs and poliosis


# Differential diagnosis

1. Inflammatory
  - Vogt-Koyanagi-Harada Disease
  - Sympathetic ophthalmia
  - Sarcoidosis
  - White dot syndrome
  - Uveal effusion syndrome
  - Posterior scleritis
  - Severe central serous retinopathy
2. Infectious
  - Lyme disease, TB
3. Infiltrative
  - Primary intraocular B-cell lymphoma
4. Other systemic disorder
  - Uncontrolled hypertensive retinopathy ->BP 140/82
  - Toxemia of pregnancy



# Investigation

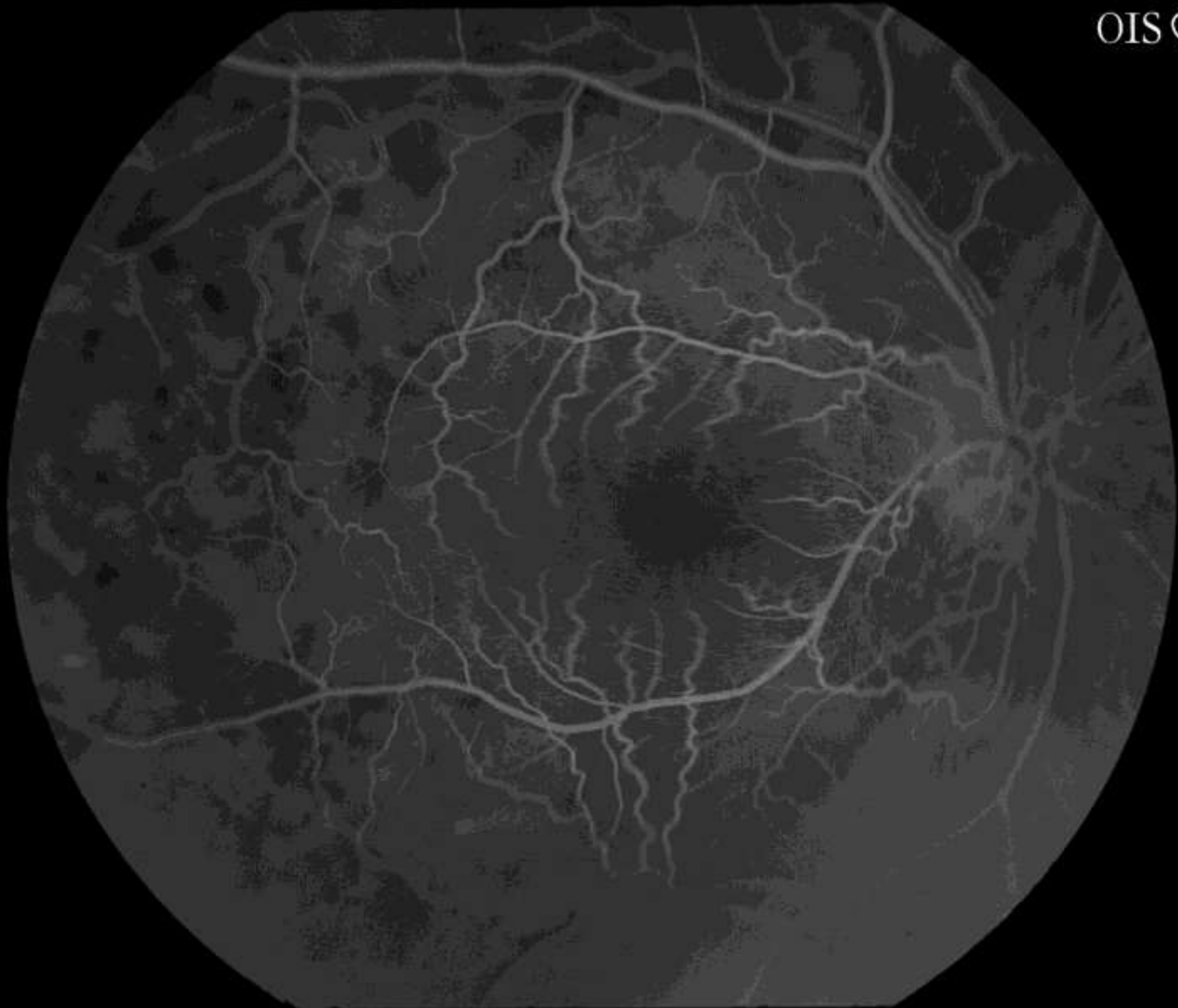
## ■ Serologies;

- CBC
  - UA
  - ACE 35 U/L
  - Lysozyme 6.1mcg/ml
  - Complement component
  - ANA, RF, ssDNA
  - Sed rate, CRP
  - Lyme Ab, FTA-abs, Bartonella, TB testing
  - Positive for CMV IgG, EBV IgG, HSV 1 IgG
- 
- WNL

# FA& ICG

00:00.00  
50°  
OD

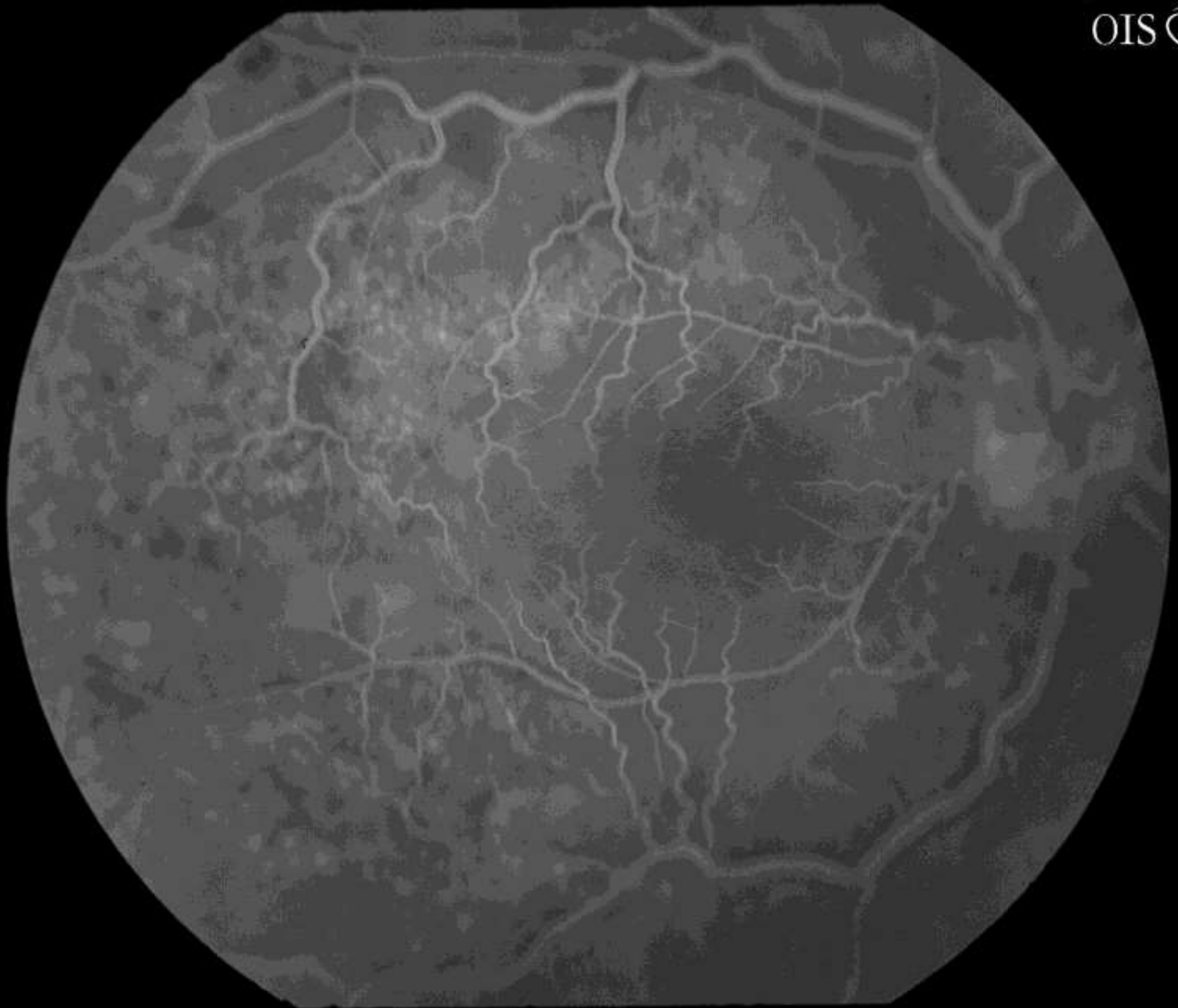
OIS 



10/25/2012  
5

00:10:15  
50°  
OD

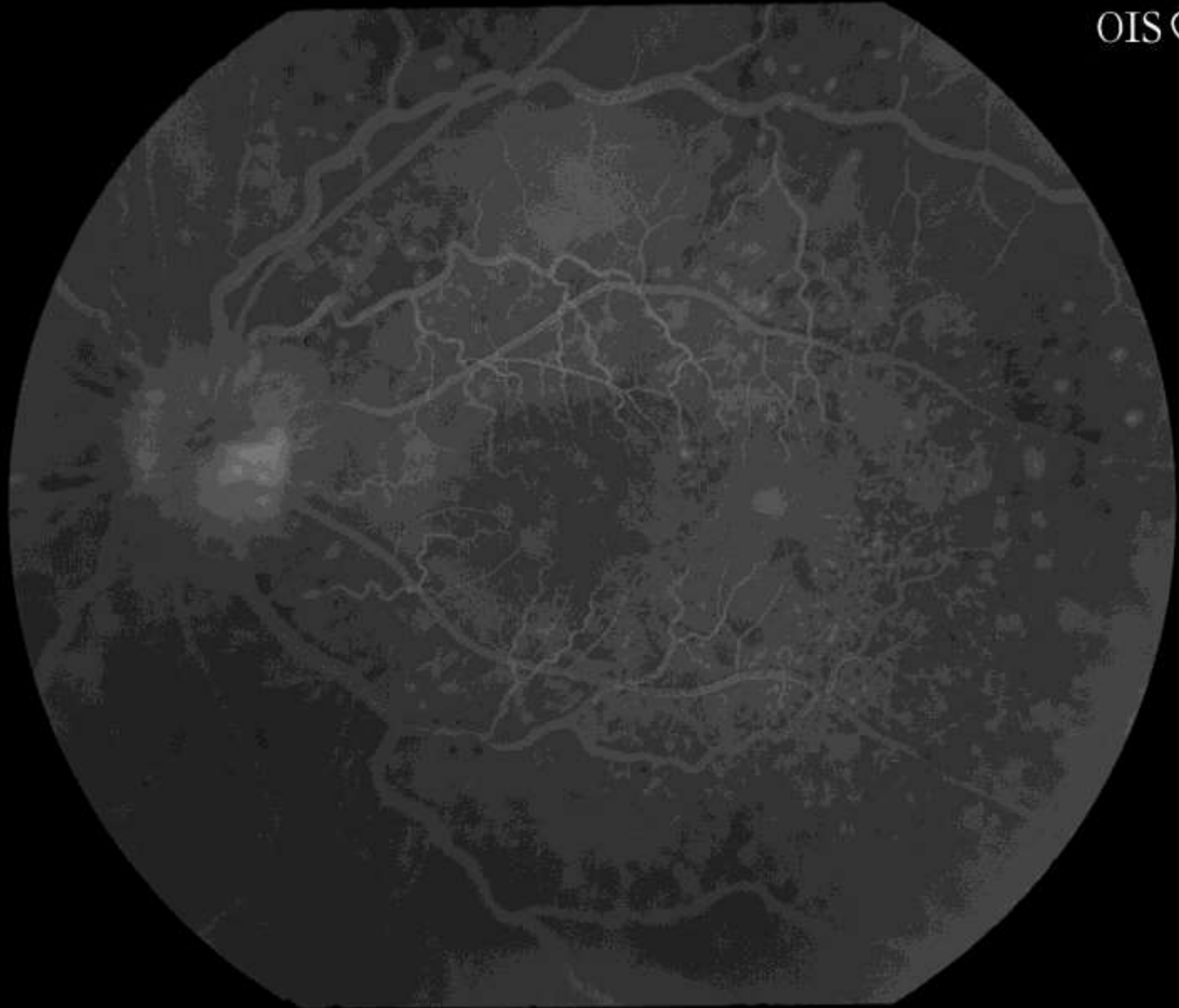
OIS 



10/25/2012  
11

00:16.44  
50°  
OS


OIS 



10/25/2012  
13

00:17.84  
50°  
OS

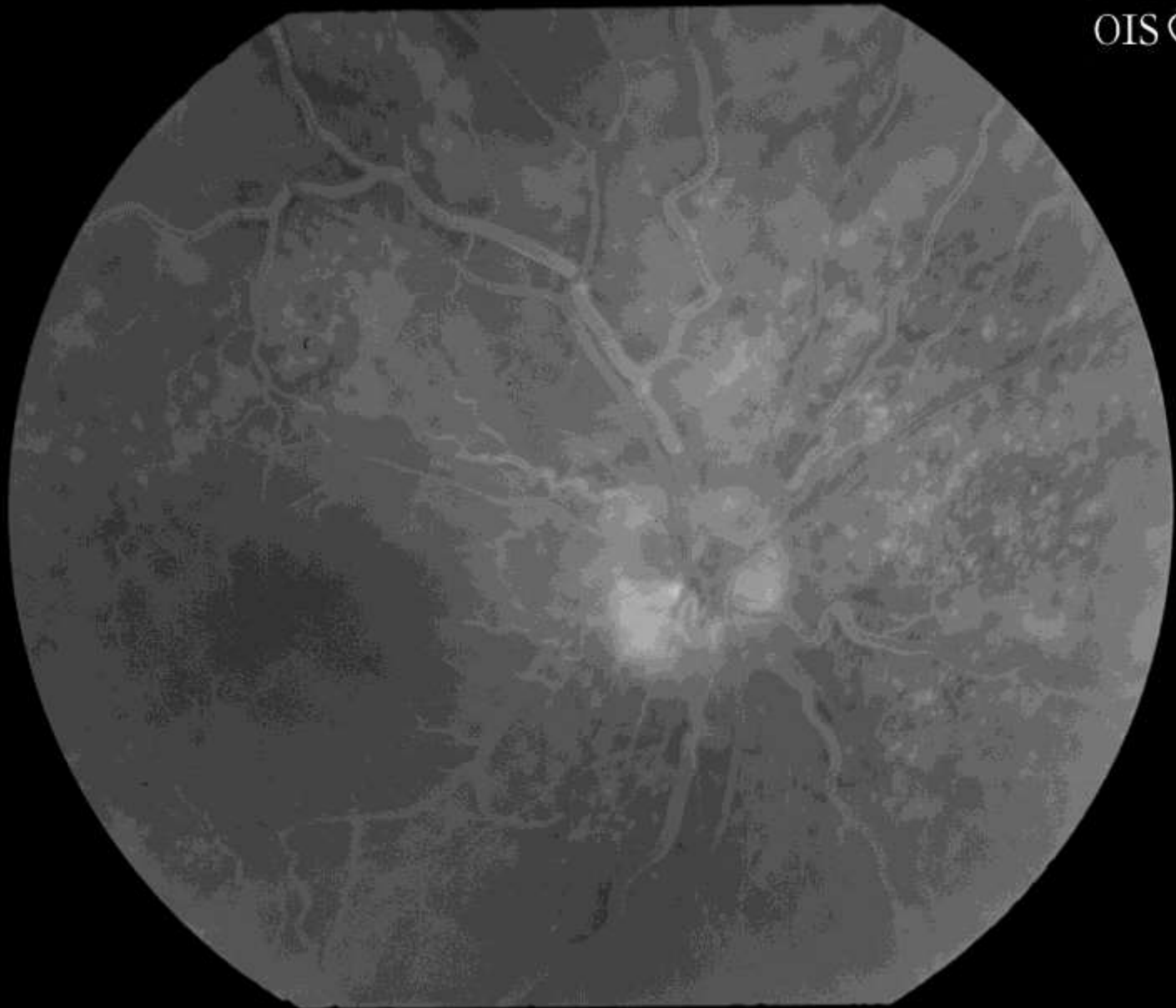
OIS 



10/25/2012  
14

00:31.09  
50°  
OD

OIS 

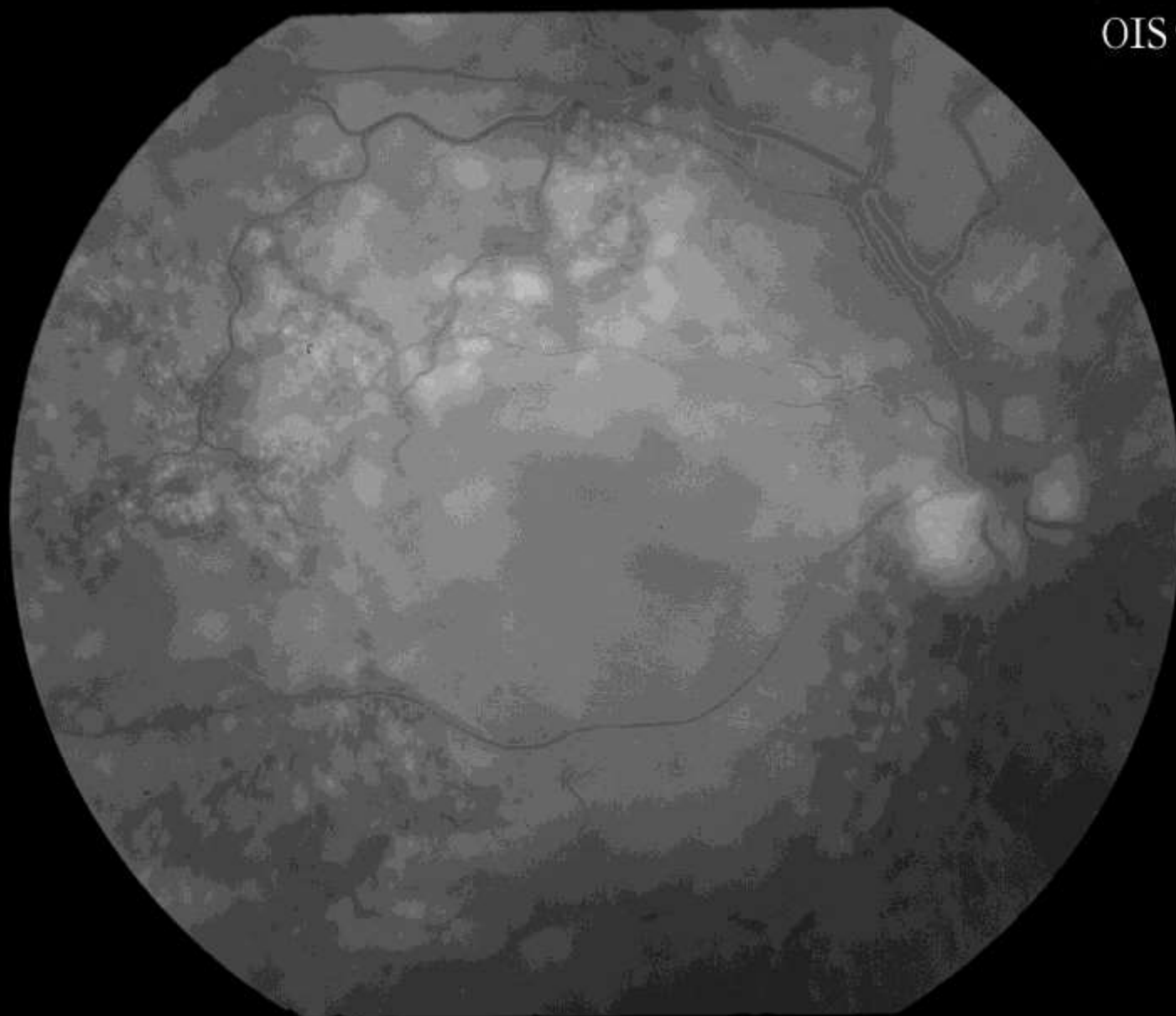

10/25/2012  
18



02:26.85  
50°  
OD

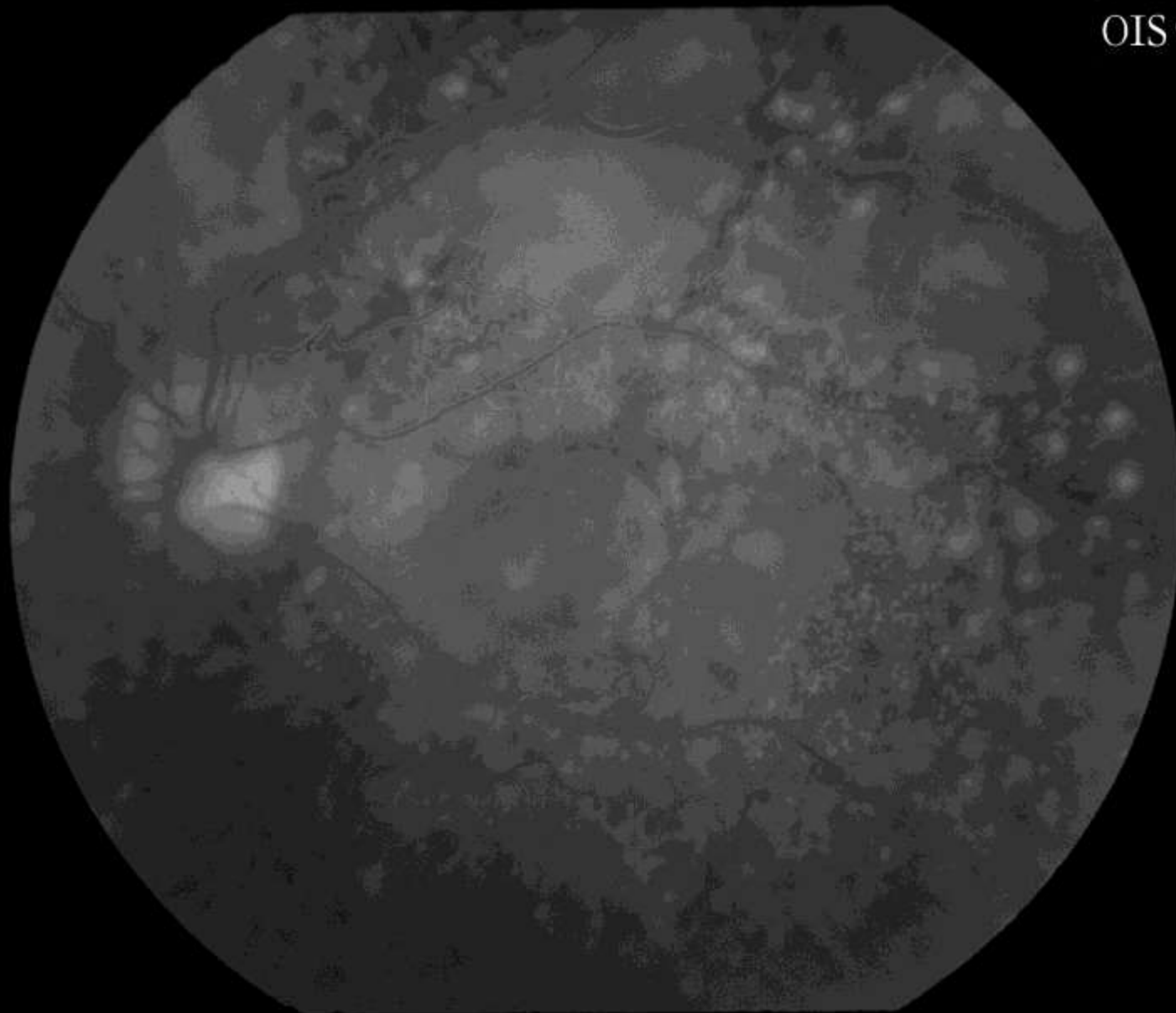
OIS 



10/25/2012  
36

02:32.97  
50°  
OS

OIS 

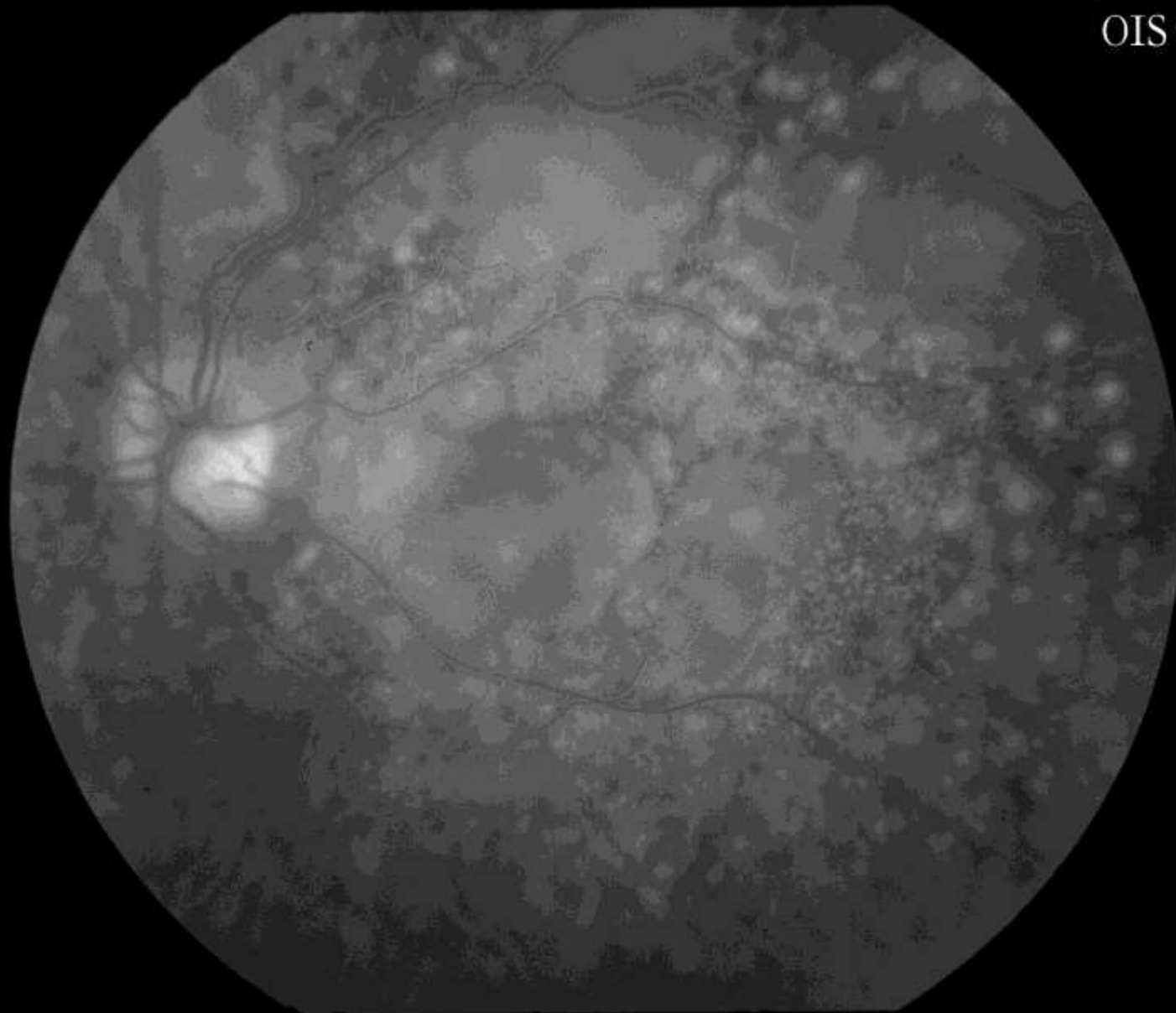

10/25/2012  
38



02:37.24  
50°  
OS

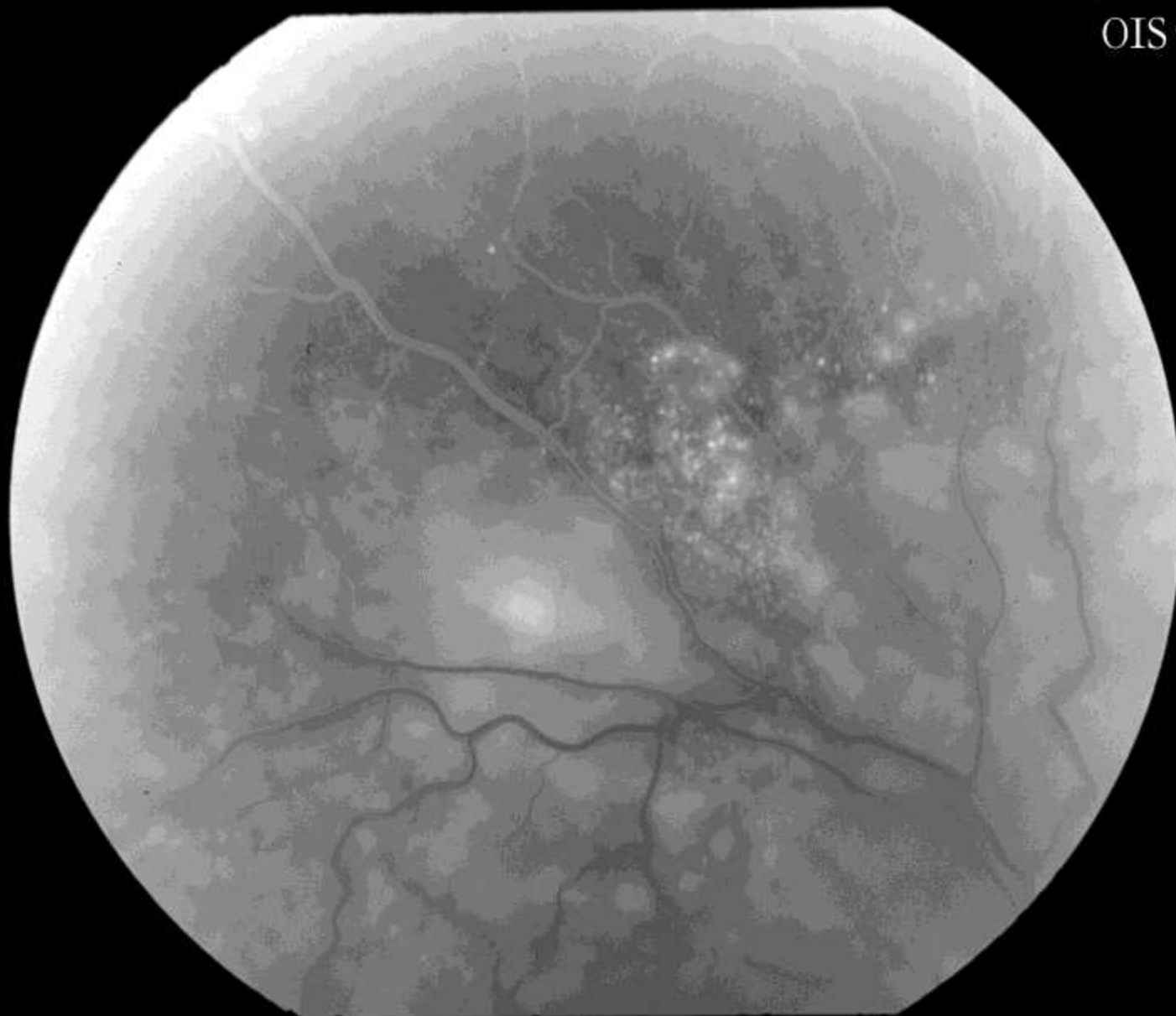
OIS 



10/25/2012  
40

04:08.75  
50°  
OD

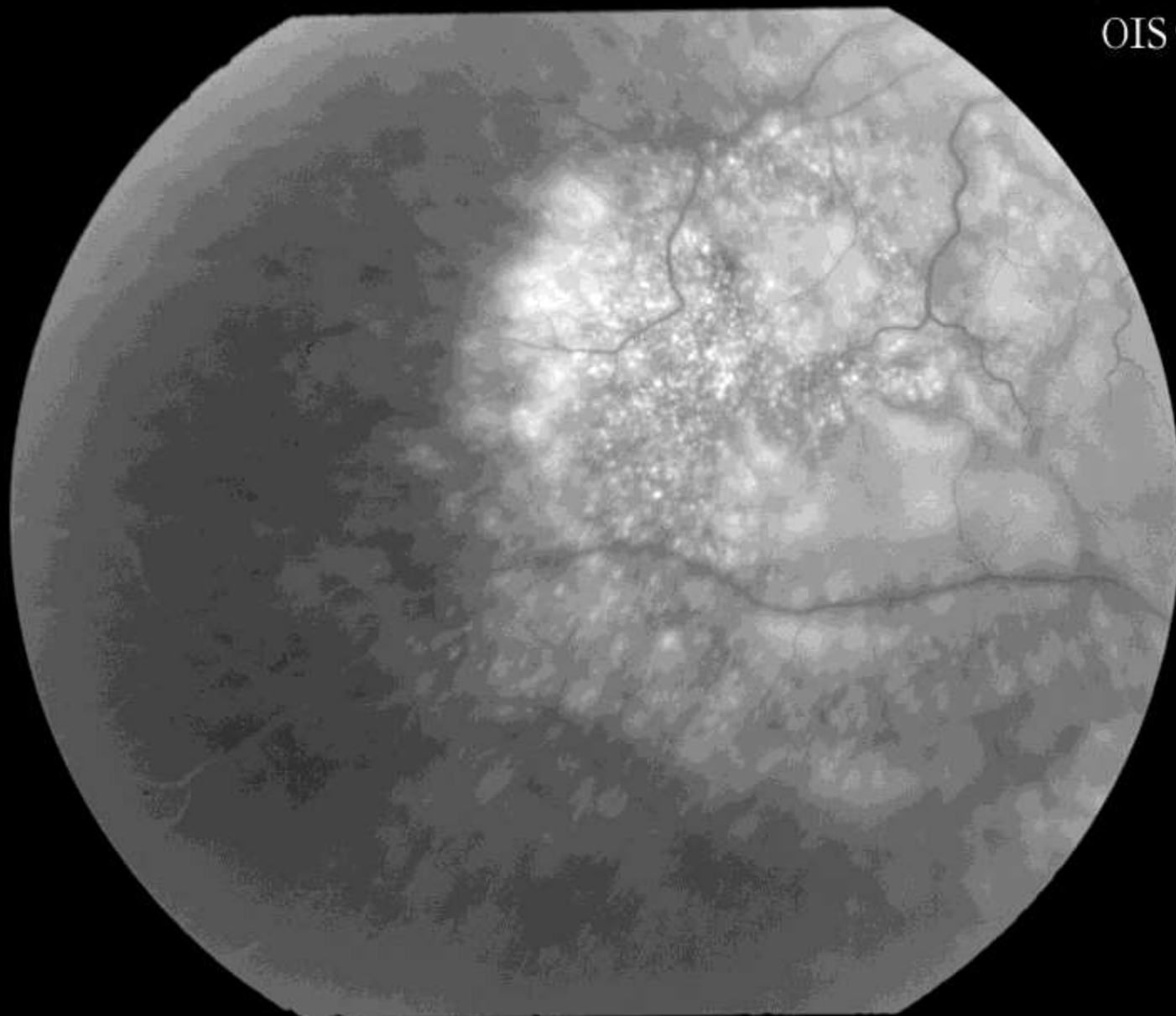
OIS 



10/25/2012  
48

04:25.84  
50°  
OD

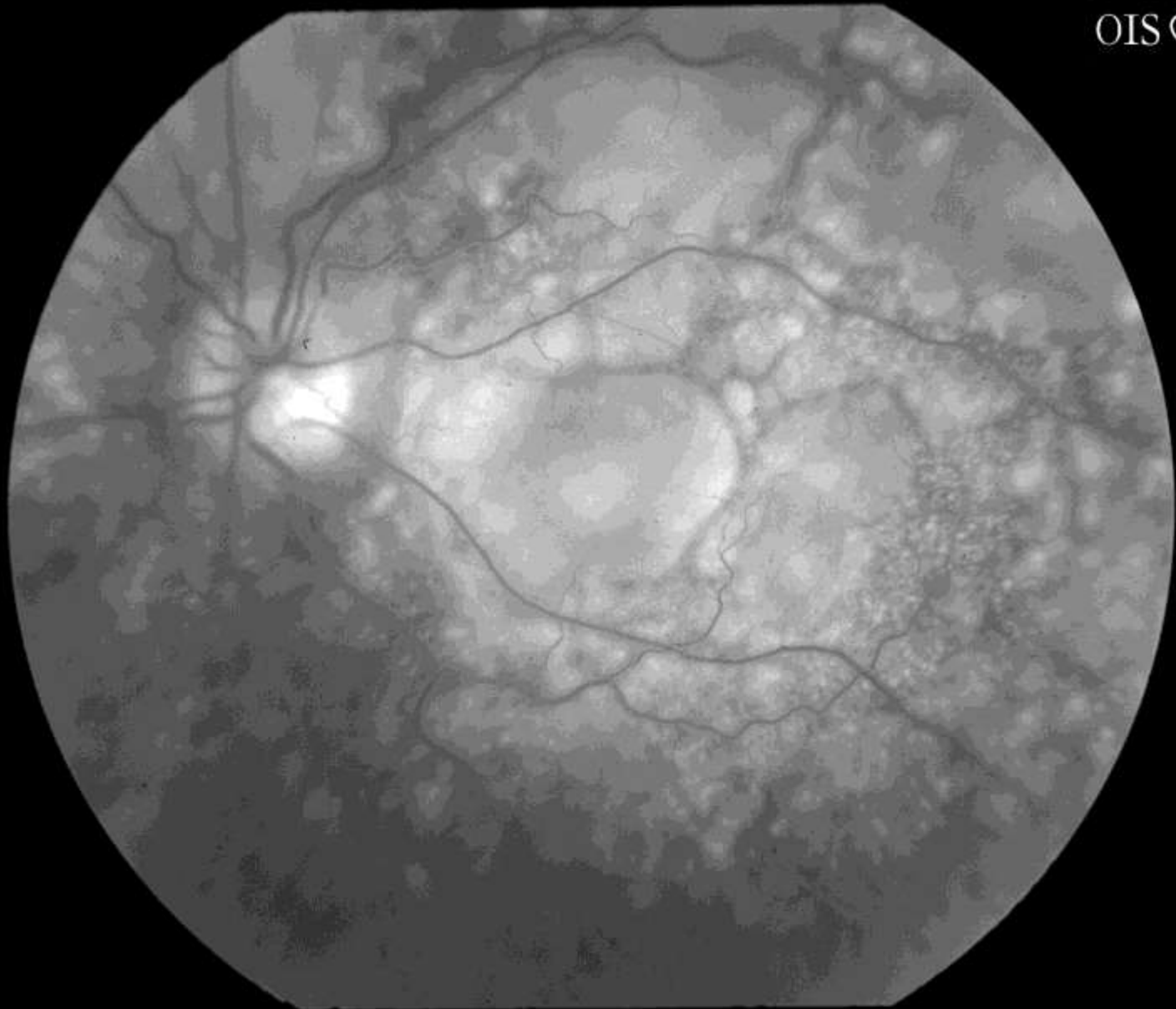
OIS 



10/25/2012  
51

04:47:69  
50°  
OS

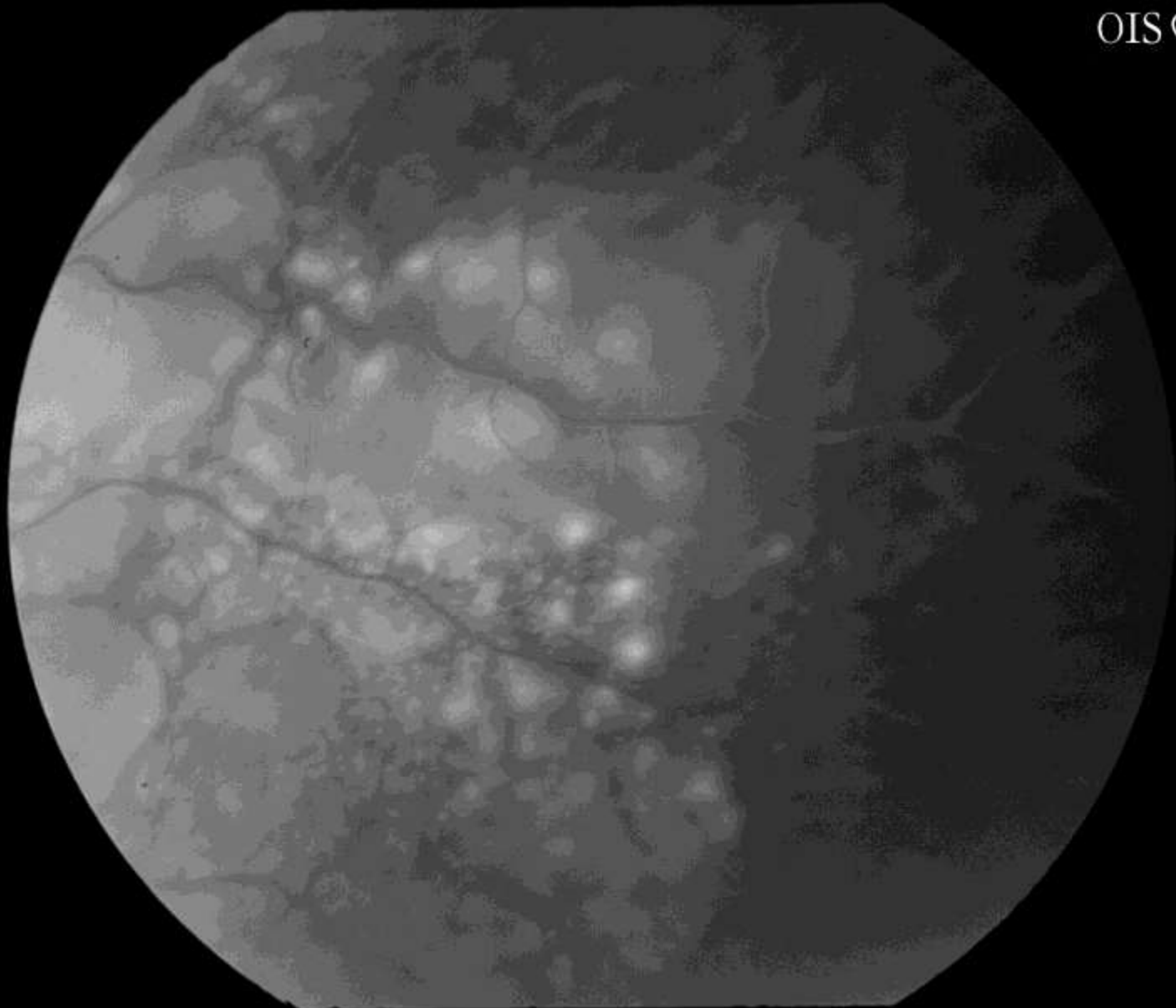
OIS 



10/25/2012  
56

05.04.95  
50°  
OS

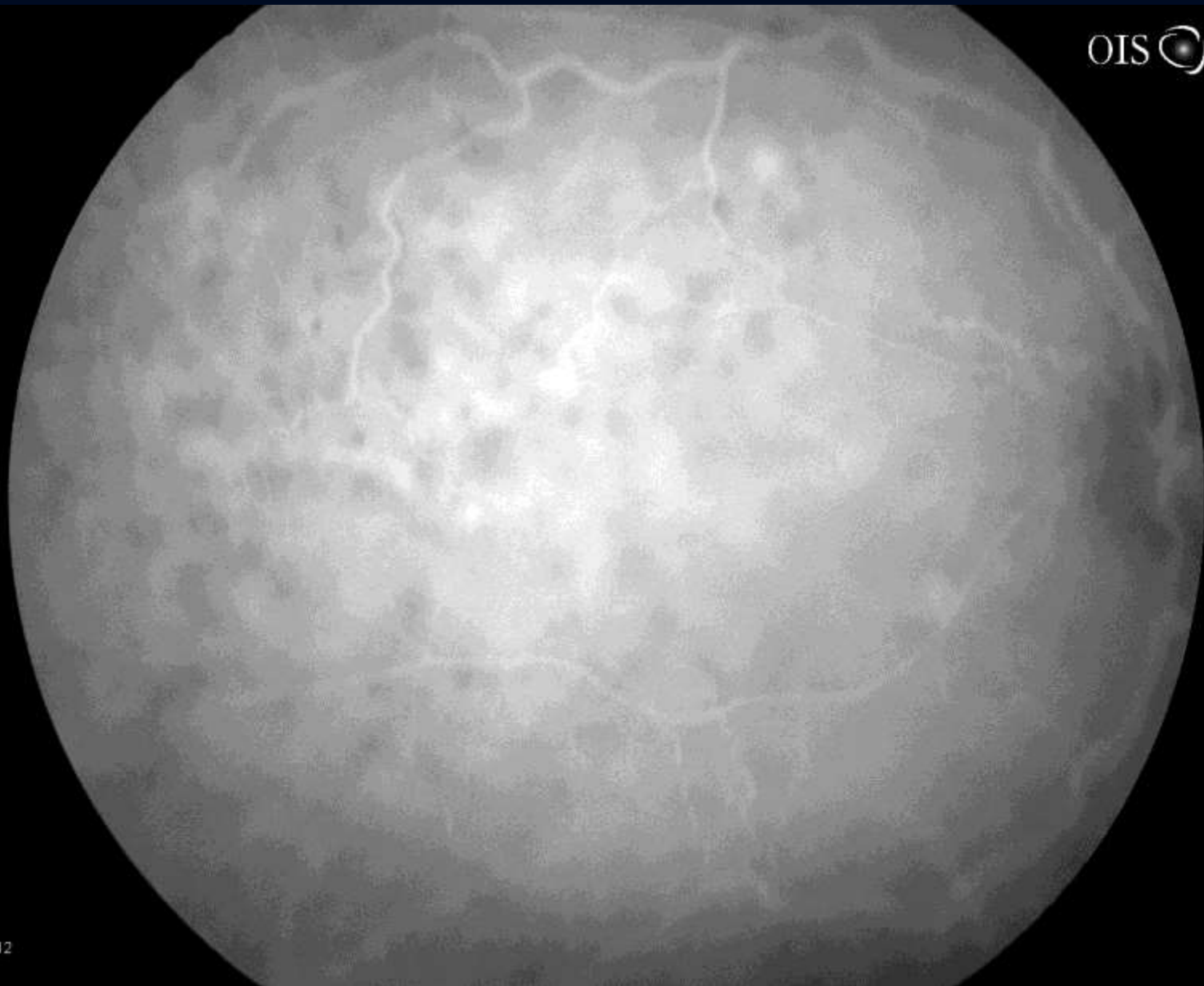
OIS 



10/25/2012  
61

04:46:21  
50°  
0D

OIS 

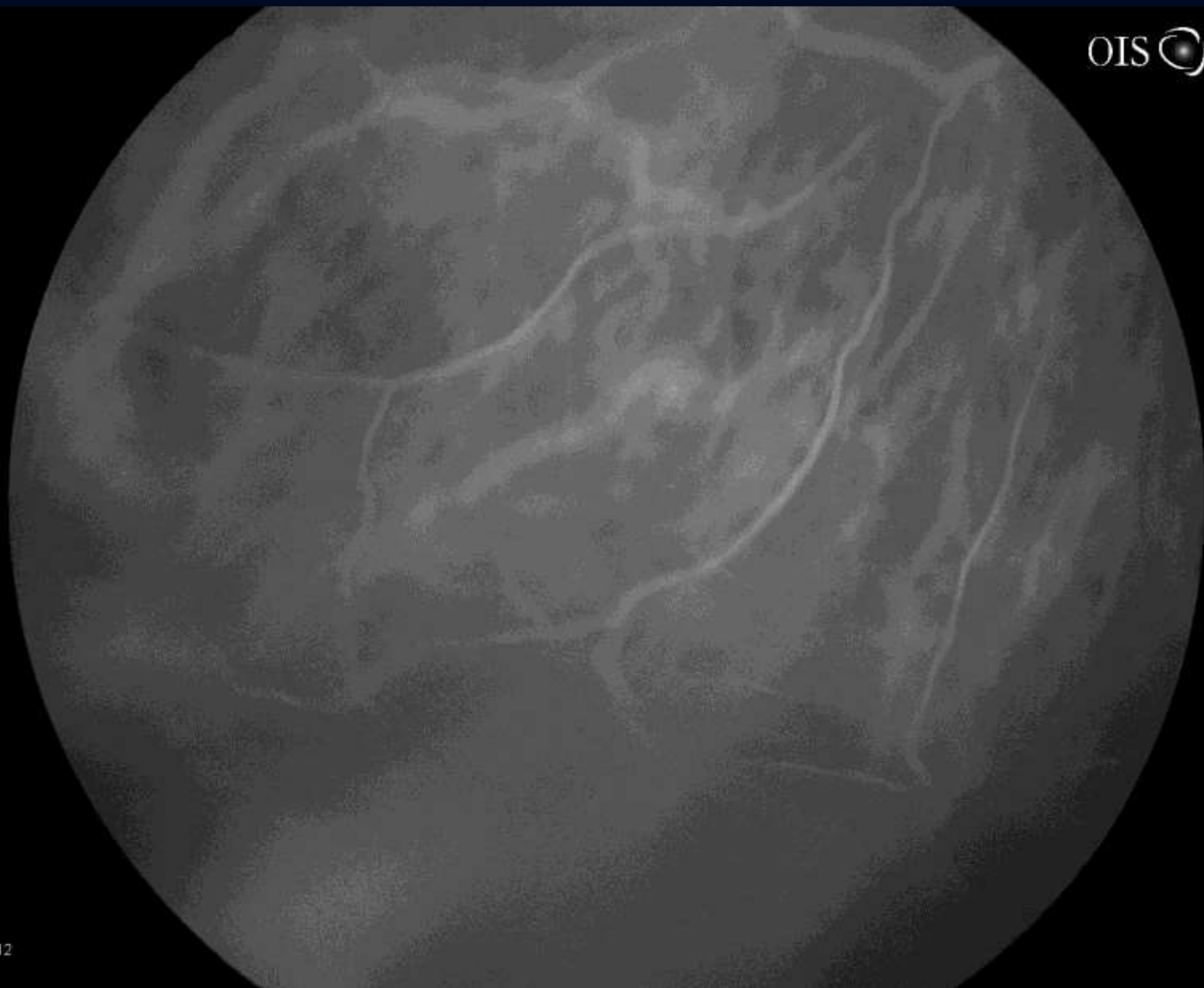

10/25/2012  
66



05:10:36  
50°  
0D

OIS 




10/25/2012  
72

05:22:00  
50°  
0S

OIS 

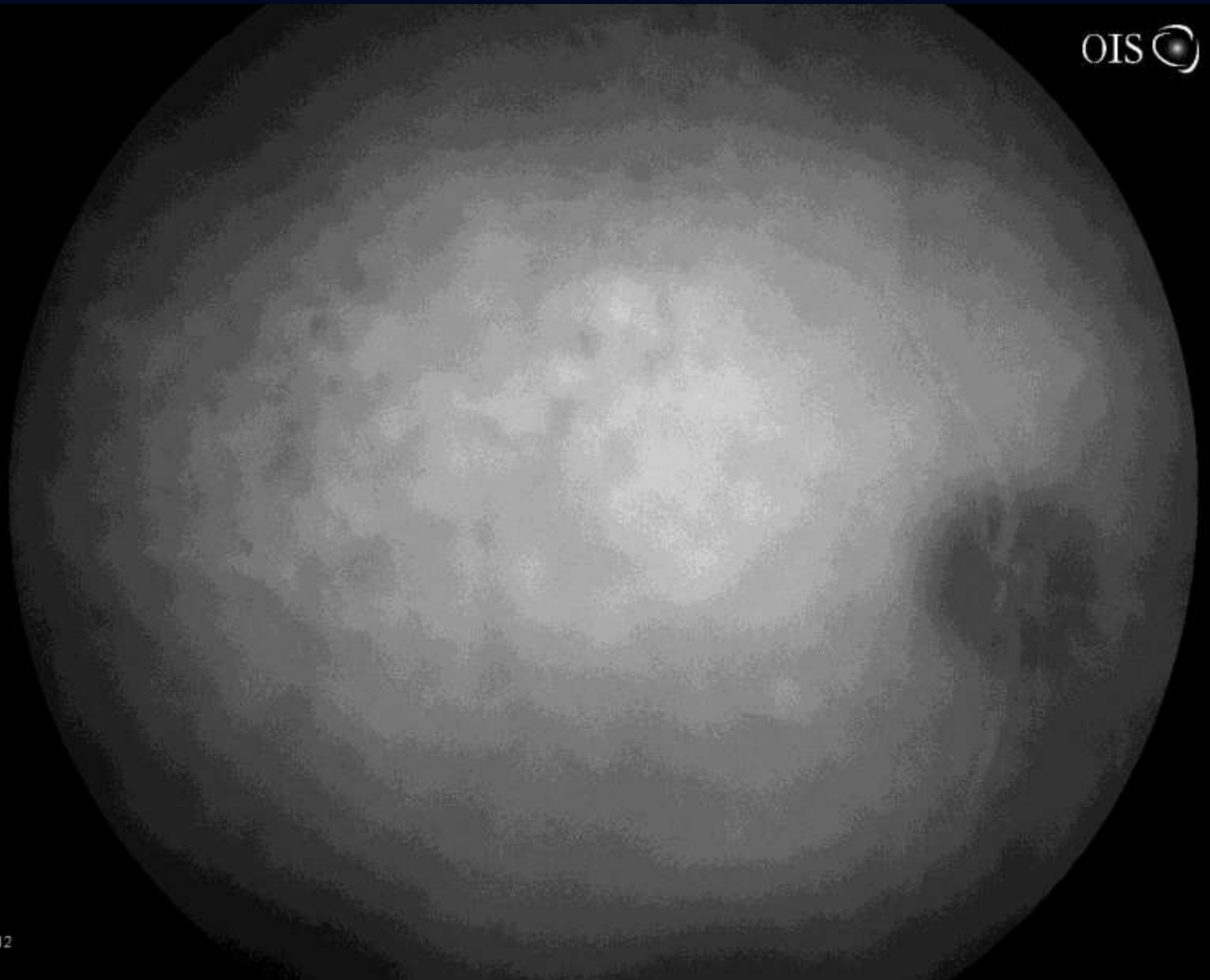
10/25/2012  
75





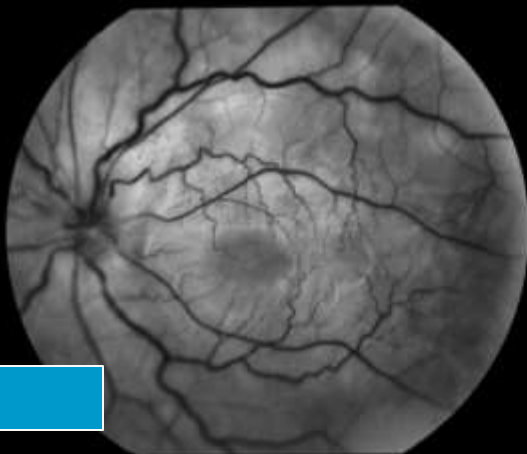
10:11.49  
50°  
0D

OIS 

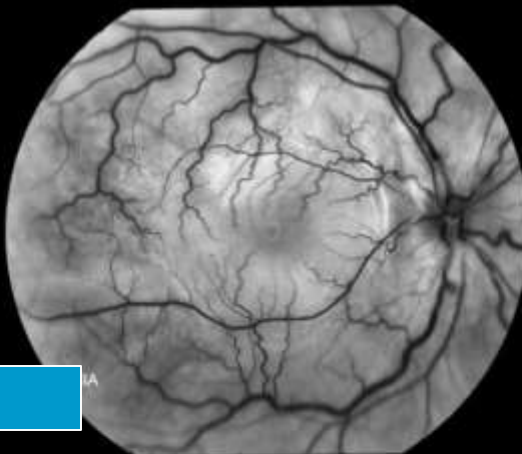


10/25/2012  
85

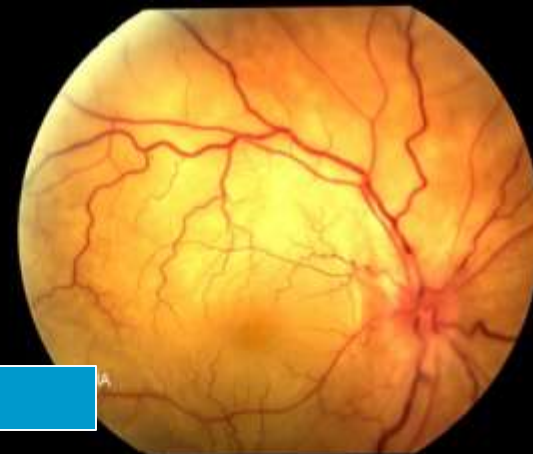50°  
OS



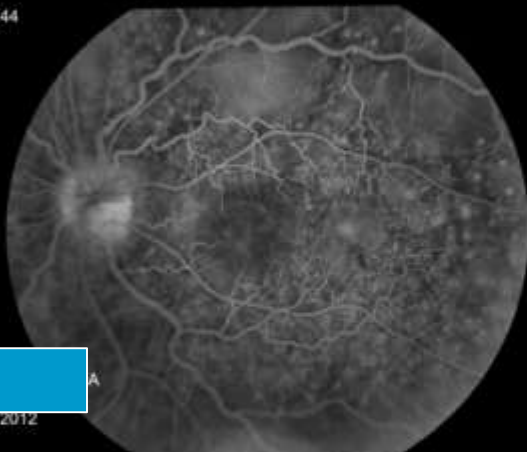
50°  
OD



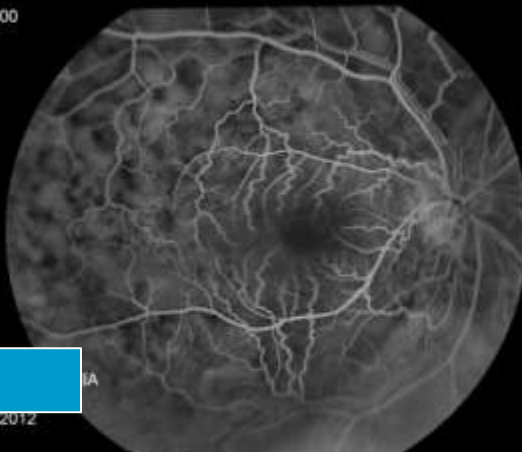
50°  
OD



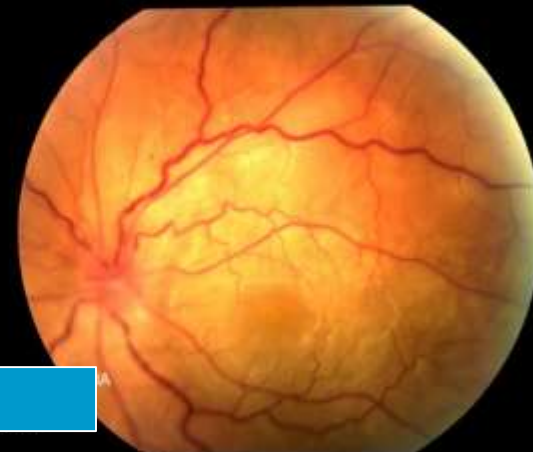00:16.44  
50°  
OS



00:00.00  
50°  
OD

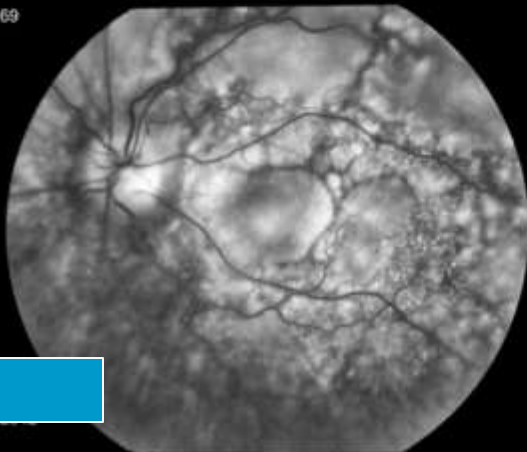


50°  
OS



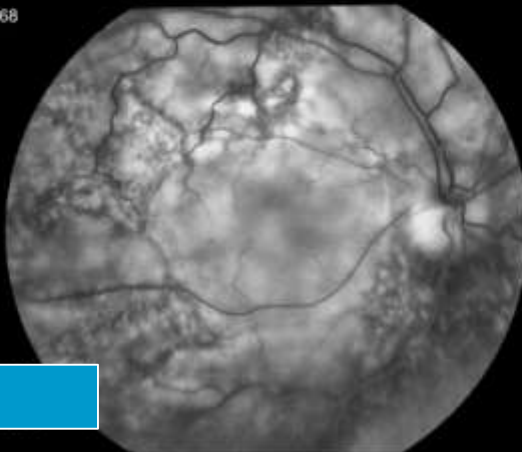
10/25/2012  
13

04:47.69  
50°  
OS

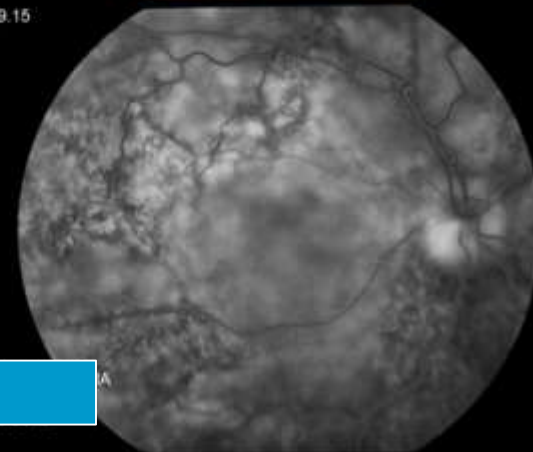


10/25/2012  
5

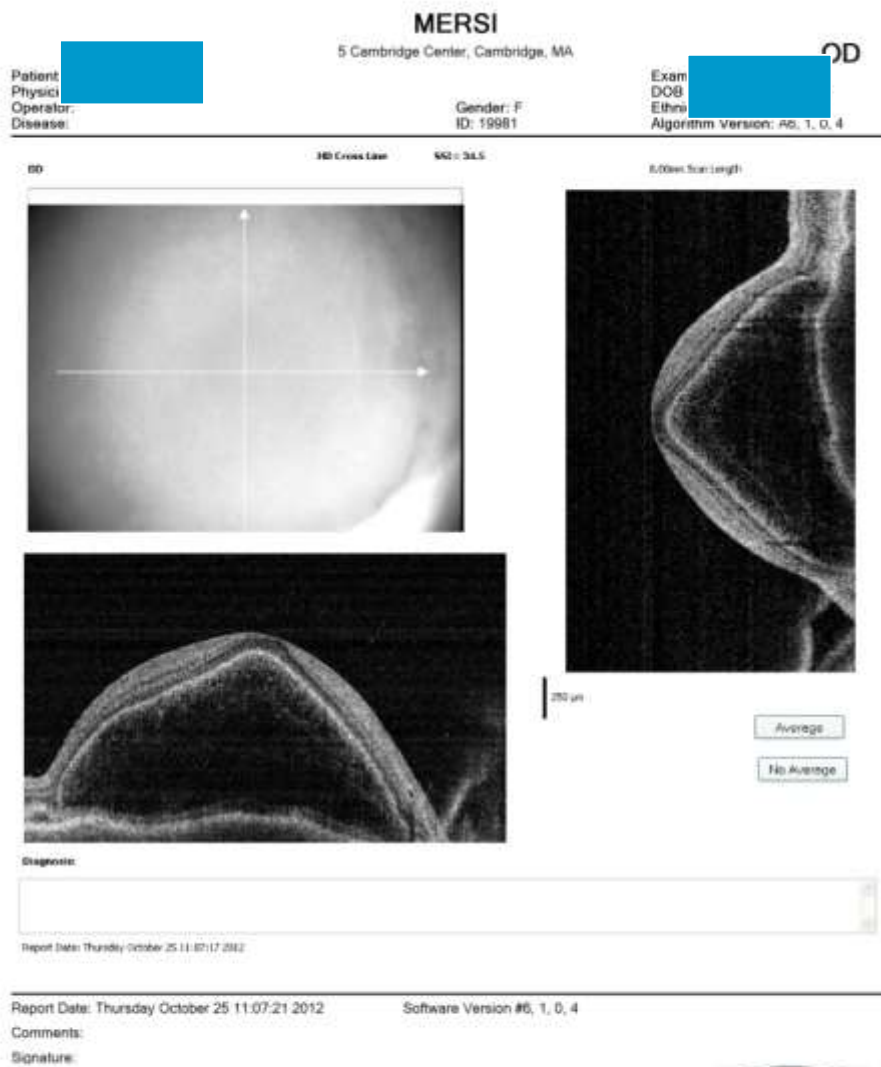
03:53.68  
50°  
OD



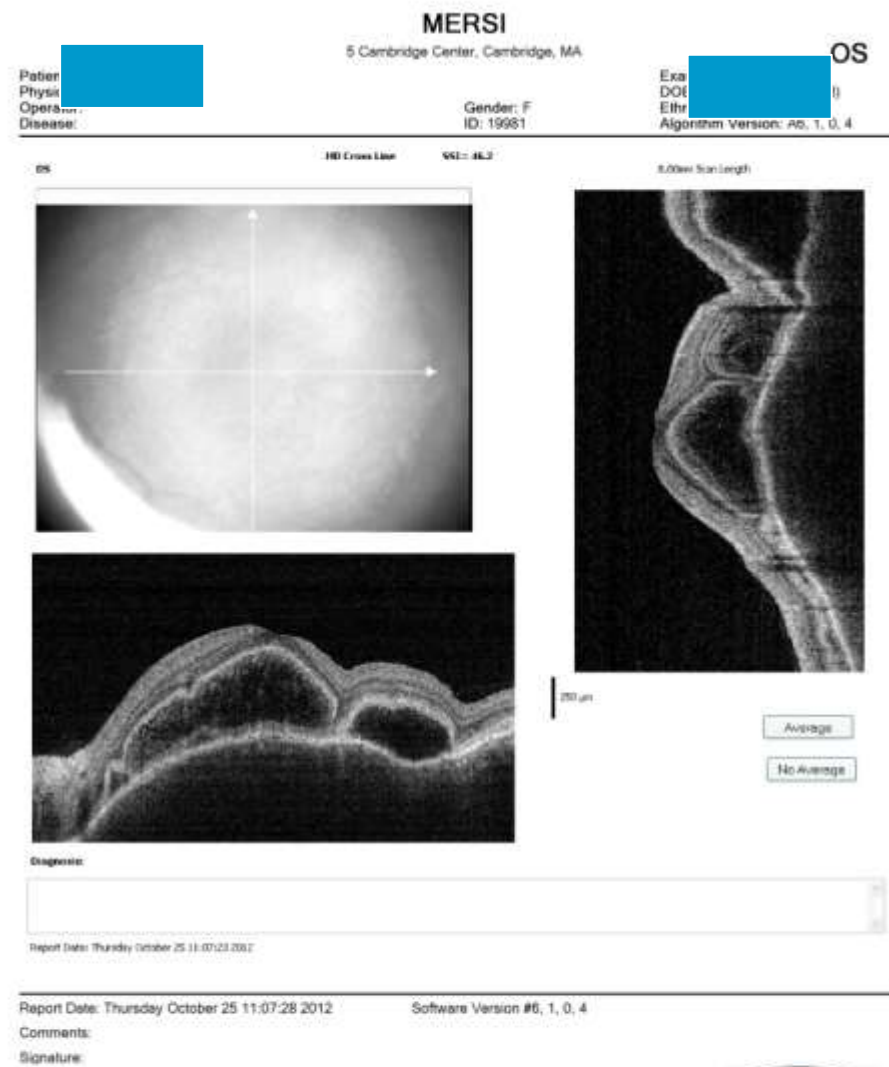
02:29.15  
50°  
OD



# OCT



Defining the OCT Revolution



Defining the OCT Revolution



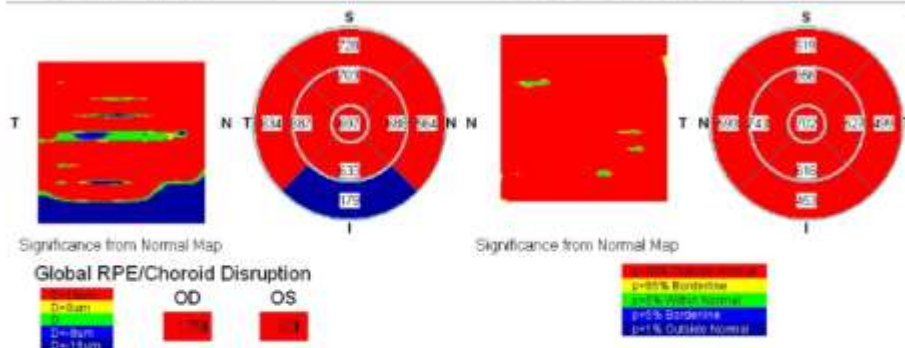
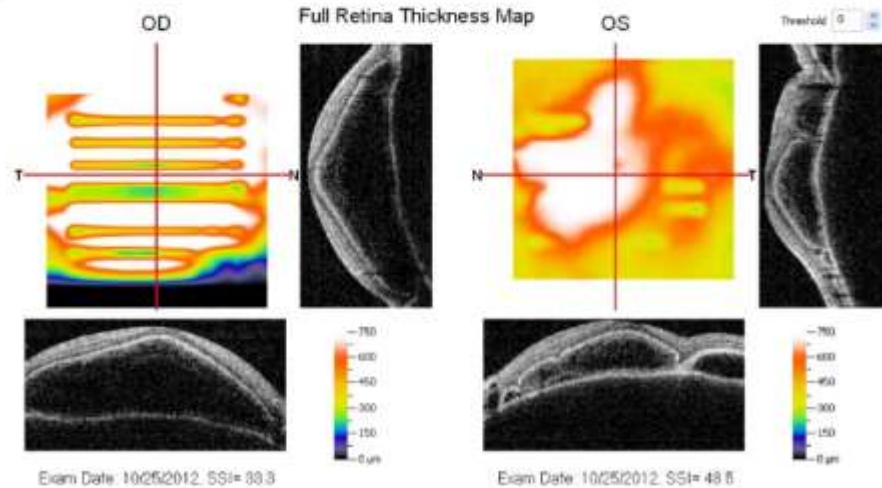
**MERSI**  
5 Cambridge Center, Cambridge, MA  
Macula Map(EMM5) Retina Report

OD/OS

Patient: [REDACTED]  
Physician: [REDACTED]  
Operator: [REDACTED]  
Disease: [REDACTED]

Gender: F  
ID: 19981

Exam I  
DOB: [REDACTED]  
Ethnic: [REDACTED]  
Algorithm Version: A6, 1, 0, 4



Report Date: Thursday October 25 11:07:14 2012

Software Version #6, 1, 0, 4

Comments:

Signature:

Defining the OCT Revolution



CRT 697, 702

# Problem lists

- Sudden visual loss with serous retinal detachment OU
  - Associated with headache, malaise and weakness of the legs and poliosis

Vogt-Koyanagi-Harada Disease



# Treatment 10/25/12

- IV Solumedrol 1 g/d x2 days
- Prednisolone 50mg PO QD
- Start cellcept 1 g PO twice a day
- Recommended to see neurologist to get LP for CSF analysis

# Follow-up 1 weeks (11/2/12)

- Reported better vision immediately after iv solumedrol, but blurred again 3 days after, with headaches
- VA: Fc3 ft, 20/400 ph 20/80  
IOP 16 OU
- Slit lamp: A/C - cell trace OD, 0.5+ OS
- Fundus:
  - disc - hyperemia, blurred margin OU
  - Vessels – tortuosity OU
  - Extensive exudative retinal detachments OU

# Follow-up 1 weeks (11/2/12)

- 1 gm Solumedrol infusions at MERSI x 2 days
- Admitted to MGH for neurologic work up
- MRI revealed posterior uveal thickening with enhancement, prominent left greater wing, Arachnoidal granulation
- LP



# CSF analysis at MGH

- Colorless
- Glucose 97 (H)
- Total Protein 20
- Xanthochromia None
- RBC 1
- Neutrophils 0%, Bands CSF 0%
- Lymphs 97%, Reactive Lymphs 0%,
- Monos 3%, Eos 0%, Basos 0%, Macrophages/Lining Cells 0%
- Anion Gap 15
- Eos# 0.00, Baso# 0.01, Lymph# 1.42, Mono# 1.23 (H), Neutrophil # 14.44 (H)
- Diff Method Auto, Blasts, CSF (%) 0, NRBC#, auto 0.00, GFR (estimated) > 60, NRBC(%) 0, Nucleated cells, CSF 49 (H)

# Discharge from MGH 11/6/12

- Medications;

- cellcept 1 g PO twice a day
- Prednisolone 50mg PO

Add

- Mepron suspension 1500 mg PO QD
- Omeprazole 40mg PO QD

# Follow-up at MERSI (11/9/12)

- Reported significant improvement of vision OU, improved general complaints of headache and weakness.
- VA 20/40 OD, 20/50 OS  
IOP OD 13, OS 15 mmHg
- Slit lamp: A/C OD-cell trace, OS-quiet
- Fundus:
  - Disc - hyperemia, indistinct margins OU
  - Vessels – slight tortuosity OU
  - Exudative retinal detachments OU - decreased

# Follow-up at MERSI (11/9/12)

- Patient education about the nature of her condition and the requirements of treatment discussed
- Continue on Prednisone 50mg/d and CellCept 2g/d.



# VKH revised criteria

1. No history of penetrating ocular trauma
2. No evidence of other ocular or systemic diseases
3. Bilateral ocular disease; either a or b:
  - a. Early manifestations:
    - i. Diffuse choroiditis manifested as either:
      1. Focal areas of subretinal fluid or
      2. Bulous serous retinal detachment
    - ii. If equivocal fundus findings, then both of below:
      1. Fluorescence angiography showing focal delayed choroidal perfusion, pinpoint leakage, pooling within subretinal fluid, and optic nerve staining
      2. Ultrasound showing diffuse choroidal thickening without posterior scleritis
  - b. Late manifestations
    - i. History suggestive of above, and both ii and iii or multiple from iii
    - ii. Ocular depigmentation
      1. 'Sunset glow' Fundus
      2. Sugiura sign
    - iii. Other ocular signs:
      1. Nummular chorioretinal depigmented scar
      2. RPE (Retinal pigment epithelium) clumping or
      3. Recurrent or chronic anterior uveitis
4. Neurological or auditory:
  - a. Meningismus
  - b. Tinnitus
  - c. Pleocytosis in cerebrospinal fluid
5. Skin symptoms:
  - a. Alopecia
  - b. Poliosis
  - c. Vitiligo

## Complete VKH:

-shows all the symptoms 1-5

## Incomplete VKH:

-symptoms 1-3 plus 4 or 5

## Probable VKH:

- only show symptoms 1-3

Read RW, Holland GN, Rao NA, Tabbara KF, Ohno S, Arellanes-Garcia L, Pivetti-Pezzi P, Tessler HH, Usui M: Revised diagnostic criteria for Vogt-Koyanagi-Harada disease: report of an international committee on nomenclature, Am J Ophthalmol 2001, 131:647-652

# Vogt-Koyanagi-Harada syndrome

- is an uncommon multisystem inflammatory disorder characterized by panuveitis with serous retinal detachments, and it is often associated with neurologic and cutaneous manifestations, including headache, hearing loss, vitiligo and poliosis.

Because of its varied clinical manifestations, the American Uveitis Society adopted in 1978 the following diagnostic criteria for VKH: No history of ocular trauma or surgery, and at least three of the following four signs, 1) bilateral chronic iridocyclitis, 2) posterior uveitis with any of the following:

- multifocal exudative retinal or retinal pigment epithelial detachments,
- disc hyperemia or edema, or
- “sunset glow” fundus, which is a yellow-orange appearance of the fundus due to depigmentation of the RPE and choroid, 3) neurologic signs, including tinnitus, neck stiffness, cranial nerve or central nervous system symptoms or cerebrospinal fluid (CSF) pleocytosis or 4) cutaneous findings, including alopecia, poliosis or vitiligo.

## ■ Stages of Disease

Four clinical stages have been described in VKH: prodromal stage, acute uveitic stage, convalescent stage and chronic recurrent stage. Experience shows that the stages of VKH are often indistinct. Moreover, it is not clinically relevant to distinguish the stages for a treatment strategy. The critical aspects of treatment are to make the correct diagnosis without delay, to institute appropriate systemic anti-inflammatory therapy, and to taper therapy appropriate to disease activity and side effects.

**Stage 1: Prodromal.** This stage, also called the meningeal stage, lasts for a few days to a few weeks and often mimics a viral infection. Patients present with fever and neurologic features, including meningeal involvement (headache, confusion, neck stiffness), encephalopathy (convulsions, paresis, aphasia), focal neurologic signs (cranial nerve palsies, hemiparesis, optic neuritis), auditory symptoms (tinnitus, vertigo, hearing loss) and CSF lymphocytosis. Some patients report a hypersensitivity of their scalp and skin to touch.

**Stage 2: Acute uveitic.** The second stage occurs within three to five days of the prodromal stage and lasts for several weeks. Patients often do not present to their ophthalmologist until this stage, when they experience acute ocular pain and red eyes associated with bilateral blurring of vision secondary to uveitis. Posterior segment involvement includes multifocal choroiditis with choroidal inflammation and thickening, Dalen-Fuchs nodules and disc hyperemia or edema. A hallmark finding is multifocal detachments of the neurosensory retina.

Eventually the inflammation extends into the anterior segment. Patients with VKH may have chronic bilateral granulomatous iridocyclitis with mutton-fat keratic precipitates, iris nodules and shallow anterior chambers due to ciliary edema and suprachoroidal fluid collection. As a result, secondary complications such as posterior synechiae, pupillary membrane, glaucoma and cataract are common.

**Stage 3: Convalescent.** The convalescent stage follows the acute uveitic stage gradually, usually a few months later, and may last months or years. Findings include vitiligo, alopecia and poliosis. These skin changes generally persist despite therapy. There is also uveal depigmentation, resulting in a “sunset glow” within two to six months.

**Stage 4: Chronic recurrent.** This stage may interrupt the convalescent stage. Studies report recurrence rates of 43 percent within the first three months and 52 percent within the first six months, often associated with rapid tapering of corticosteroids.<sup>1</sup> Recurrence mainly involves anterior uveitis. In this stage, complications of VKH such as glaucoma, cataract, subretinal neovascular membrane and subretinal fibrosis may develop.



## ■ Differential Diagnosis

The differential diagnosis of VKH includes the anatomical condition uveal effusion syndrome, infectious processes such as syphilis or herpes, malignancies such as leukemia or metastasis or inflammatory diseases. The main diagnoses to consider in cases with fluorescein angiographic findings are VKH, sympathetic ophthalmia, posterior scleritis and acute systemic arterial or pregnancy-related hypertension.

Sympathetic ophthalmia is histopathologically identical to VKH and can present in a similar fashion with rapid, bilateral visual loss associated with anterior segment inflammation, disc edema or hyperemia, choroidal thickening and serous retinal detachments. However, sympathetic ophthalmia is nearly always associated with a history of prior intraocular trauma or surgery.

Posterior scleritis initially may be difficult to distinguish from VKH until the “sunset glow” appears in the convalescent phase. Posterior scleritis can also present with ocular pain, redness and serous retinal detachments. However, it is usually unilateral and not associated with neurologic or dermatologic findings. Also, unique to posterior scleritis is the ultrasonographic “T sign,” or squaring of the interface between the optic nerve and the sclera, indicating the presence of fluid in the sub-Tenon’s space.

Systemic arterial hypertension and pregnancy-related hypertension may also result in serous retinal detachments. It is suspected that choroidal vascular changes predominate when acute elevation of blood pressure is present, whereas a more gradual onset of hypertension results in retinal vascular changes.

## ■ Imaging Studies

In the majority of VKH cases, the diagnosis is made clinically. However, fluorescein angiography, ultrasonography and optical coherence tomography (OCT) are often used to assist in the diagnosis.

In the acute uveitic stage, fluorescein angiography findings include multiple punctate hyperfluorescent dots at the level of the RPE (the characteristic “stars at night” appearance), which gradually enlarge and stain the subretinal fluid, delineating the serous retinal detachments. In 70 percent of cases, there is disc leakage. In the chronic recurrent stage, there are multiple hyperfluorescent RPE window defects and alternating hyper- and hypofluorescence from RPE alterations, sometimes referred to as “moth-eaten” scars. There may also be choroidal and disc neovascularization and anastomoses.

On ultrasonography, in the acute stages, VKH presents with diffuse choroidal thickening with low to medium reflectivity, serous retinal detachments, vitreous opacities without posterior vitreous detachment and scleral or episcleral thickening.

OCT is often used to diagnose and quantify subretinal fluid found in VKH. This modality also assists in following patients’ response to therapy.

Electrophysiologic tests, such as electroencephalogram, electroretinogram and electro-oculogram, are nondiagnostic. No specific serologic test exists to establish the diagnosis of VKH.

## ■ Treatment

- Early and aggressive treatment is critical. Systemic corticosteroids, particularly prednisone, are very effective in suppressing the intraocular inflammation of VKH and have a very well-characterized side effect profile. Patients typically respond immediately to corticosteroids with resolution of the exudative retinal detachment, which is a hallmark of VKH. Intravenous corticosteroids may be used if there is severe bilateral visual loss; however, hospital admission is generally not required. Patients in our retina clinic are kept on corticosteroids for up to one year with slow tapering, usually over six months. If the condition is refractory to corticosteroids or the patient is intolerant of the side effects, second-line immunosuppressive agents, particularly methotrexate (Rheumatrex, Trexall), may be considered to lower the dose of corticosteroid. Other second-line agents, including cyclosporine (Neoral, Gengraf), tacrolimus (Prograf), cyclophosphamide (Cytoxan, Neosar), chlorambucil (Leukeran), azathioprine (Azasan, Imuran) and intravenous immunoglobulin (Gamimune N, Venoglobulin-S), have also been used for treatment of VKH; however, the side effects of these agents are either more severe or less well-characterized than methotrexate.

With treatment, the visual outcome of VKH is generally good. Visual acuity is >20/40 in 50 to 90 percent of treated cases.<sup>2</sup> Visual acuity is influenced by secondary complications of VKH, including glaucoma, choroidal neovascularization, cataract, optic atrophy and phthisis bulbi.

- **Bilateral visual loss, edema**
- Given the presentation and clinical findings, our differential diagnosis included inflammatory conditions such as Vogt-Koyanagi-Harada syndrome and sarcoidosis, although the serous retinal detachments would be unusual for sarcoidosis. There were no iris nodules, and the fundus did not show sheathing of peripheral retinal veins. Furthermore, a uveitis workup including sarcoidosis, lupus and Wegener's was negative.
- Sympathetic ophthalmia, which presents identically to Vogt-Koyanagi-Harada syndrome, requires a history of penetrating ocular trauma. Malignant hypertension can present with flame-shaped hemorrhages, disc edema and serous retinal detachments, and should be considered in the differential diagnosis. However, the patient's blood pressure was well-controlled on medication. Infectious causes such as Lyme disease should be considered, as well as idiopathic uveal effusion syndrome. Neoplastic causes, especially intraocular lymphoma, need to be ruled out. MRI of the brain and MRA of the head and neck were normal. A lumbar puncture (performed by neurology) showed pleocytosis (365 white blood cells with 95% lymphocytes) and elevated protein (88 mg/dL). The opening pressure was not recorded at that time.



## ■ Discussion

- Vogt-Koyanagi-Harada (VKH) syndrome is an idiopathic multisystem inflammatory disease with bilateral uveitis. Both Vogt (1906) and later Koyanagi (1929) described patients with bilateral anterior uveitis with vitiligo, poliosis, alopecia and dysacusia. Harada described a case of posterior uveitis with exudative retinal detachment and pleocytosis of cerebrospinal fluid in 1926.
- Today, VKH is considered a single entity of bilateral granulomatous panuveitis variably associated with vitiligo, alopecia, poliosis, auditory dysfunction and central nervous system involvement.
- The disease is thought to be a T-cell mediated autoimmune disorder against melanocytes, specifically against tyrosinase proteins of all organ systems. There is a genetic predisposition in pigmented individuals, such as Asians, Hispanics, Native Americans, Asian Indians and Middle Easterners. Women are affected more often than men. VKH is most common in the third to fifth decade of life.
- The disease evolves in four phases. A prodromal phase with nonspecific symptoms is followed by the uveitic phase, lasting from 3 to 5 days, which presents with blurred vision, photophobia, ocular pain, bilateral granulomatous uveitis, choroiditis, exudative retinal detachments and disc edema. Upon treatment, the convalescent phase is characterized by improvement of the uveitis, subsiding serous retinal detachments and loss of melanocytes, before the disease enters the chronic/recurrent phase, which is often associated with complications due to the disease itself or due to the treatment of VKH with steroids

- Complications include cataracts, glaucoma, choroidal neovascular membranes and subretinal fibrosis. The diagnostic workup for VKH includes a lumbar puncture, typically associated with lymphocytic predominance and elevated protein. Blood work and neuroimaging should be performed to rule out malignancy and other systemic disease. A fluorescein angiogram typically shows patchy areas of delayed choroidal perfusion with pinpoint spots of staining, window defects and optic nerve head leakage.
- The diagnostic criteria for VKH have been revised, and the disease has been categorized into the following groups: probable VKH (criteria 1 to 3), incomplete VKH (criteria 1 to 3 and either 4 or 5) and complete VKH (fulfilling all criteria 1 to 5).
- The revised diagnostic criteria are:
  - 1. No history of penetrating ocular trauma.
  - 2. No evidence of ocular/systemic disease.
  - 3. Bilateral ocular disease (early or late manifestations).
  - 4. Neurologic/auditory findings.
  - 5. Integumentary findings.

## Clinical course of VKH in four phases

Phase	Time course	Description
Prodromal	Presentation	Nonspecific symptoms: fever, headache, nausea, meningismus, vertigo, dysacusis
Uveitic	3 to 5 days	Blurred vision, photophobia, ocular pain, bilateral granulomatous uveitis, choroiditis, exudative retinal detachment, disc edema
Convalescent	Months	Retinal detachments subside, uveitis improves, loss of melanocytes: depigmentation of fundus (orange-red sunset glow)/limbus (Sugiura sign)
Chronic recurrent		Anterior uveitis without posterior inflammation, complications

Source: Brenner-Semela L, Hedges TR, McCabe F



# TREATMENT

1. Corticosteroids remain the mainstay of VKH treatment
2. Immunomodulatory Therapy (IMT)
  - Cyclophosphamide 1 to 2 mg/kg/day
  - Chlorambucil 0.1 to 0.2 mg/kg/day
  - Azathioprine 1 to 2.5 mg/kg/day
  - Cyclosporine 5 mg/kg/day
  - Tacrolimus (FK506) 0.1 to 0.15 mg/kg/day
  - Mycophenolate Mofetil 2 g/day

- As previously discussed, the T-cell-mediated damage to melanocytes might be an immunopathologic basis of this disease. Several studies support the use of cyclosporine in refractory cases, either alone or with low-dose steroids.[17](#), [18](#), [140-144](#) Nussenblatt and colleagues reported such a steroid-sparing effect after using cyclosporine A.[140](#), [141](#) Similar results were described by Wakatsuki and coworkers[142](#) and Moorthy and coworkers.[18](#) Recently, Liu et al[91](#) reported the inhibitory effect of cyclosporine and steroid on the production of IL-17 and IFN-gamma by T-cells in VKH patients. They also found that effective inhibition of both cytokines production could be achieved with a combination of low dose cyclosporine (3-5 mg/kg/day) and low dose corticosteroid and that a treatment including both drugs is more effective than a single drug regimen.
- Beltatzia and colleagues reported the use of mycophenolate mofetil in the treatment of patients with chronic refractory uveitis including VKH that fail to respond to conventional steroid treatment. They concluded that mycophenolate was well tolerated and effective in the treatment of refractory ocular inflammatory conditions.[139](#):
- Cytotoxic agents have been used in the treatment of VKH and sympathetic ophthalmia with a positive therapeutic response, but the number of patients treated is small.[18](#), [145](#) Concerns regarding their myelosuppressive and toxic side effects may have limited their use.
- Helveston and Gilmore described the use of azathioprine and intravenous immunoglobulin therapy in VKH with encouraging result

- **Biologic agents**

- The main biologic agents being used in the treatment of VKH are anti-TNF- $\alpha$  drugs. Excellent treatment results using infliximab have been reported in a handful of case series.[146-150](#) Wang and Gaudio and Nicocoli et al reported a rapid response of disease activity and long term effectiveness of infliximab treatment in their recalcitrant VKH patients.[146](#), [147](#) In their reports, monthly infliximab 5 mg/kg IV infusion was well tolerated without any adverse events. A case series by Khalifa also showed a beneficial effect of infliximab as adjunctive treatment in pediatric VKH.[150](#) Adalimumab, a human monoclonal antibody against TNF- $\alpha$  has been used in refractory cases of VKH by Diaz-Llopis with good results.[151](#), [152](#) In their series, adalimumab 40 mg subcutaneous injection every other week decreased inflammation and reduced concomitant immunosuppressive drugs required in all 3 cases.

- Daclizumab, a humanized monoclonal antibody against IL-2 receptor (CD25) had shown potential for treating noninfectious intermediate and posterior uveitis in many reports.[149](#), [153](#)-[155](#) Subcutaneous injection of Daclizumab every 2 weeks has been reported to maintain VA, reduce inflammatory activity, with concomitant reduction in other immunosuppressants in refractory uveitis patients.[153](#), [154](#)

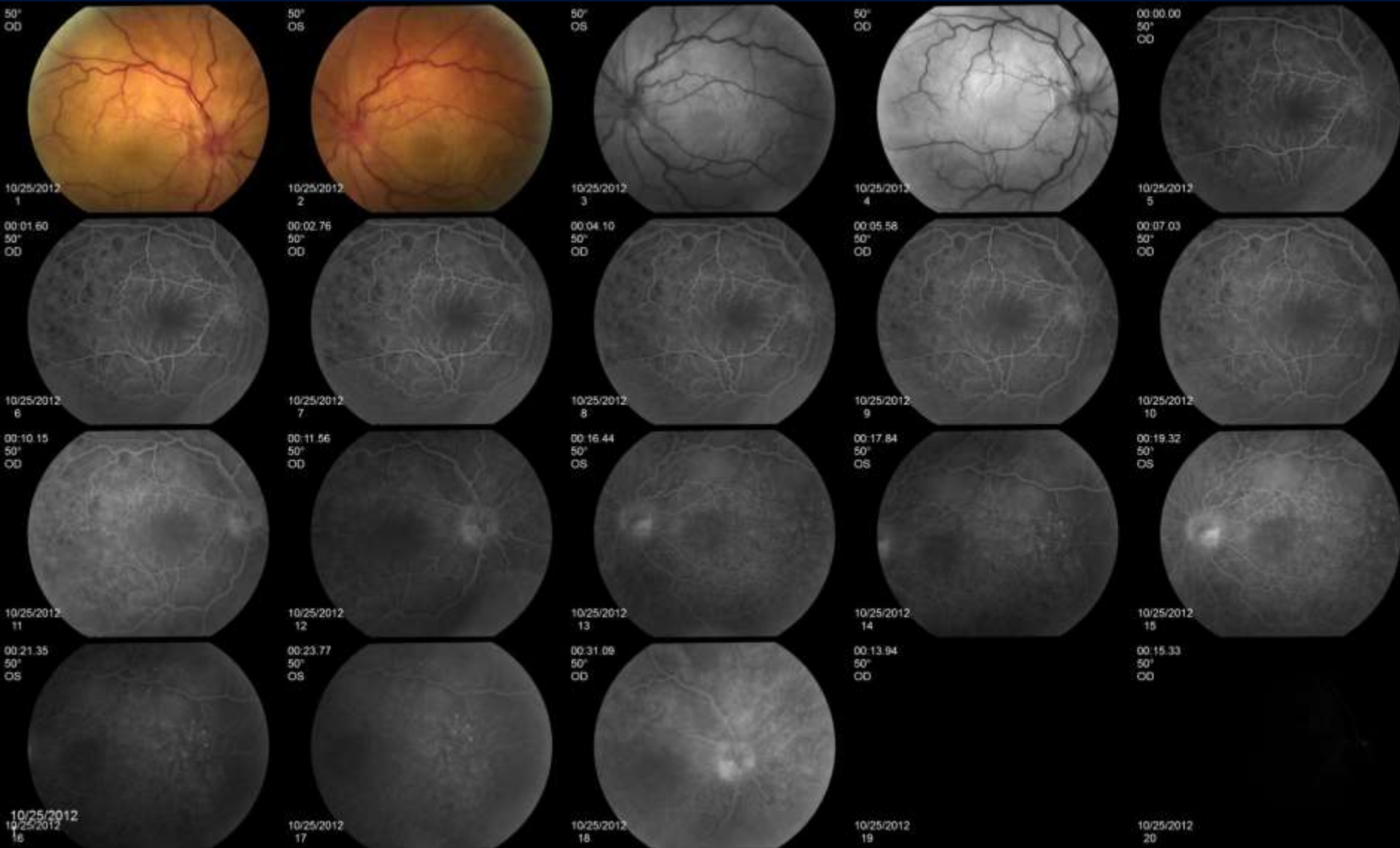
Thank you

# VKH Syndrome

## Criteria for Diagnosis

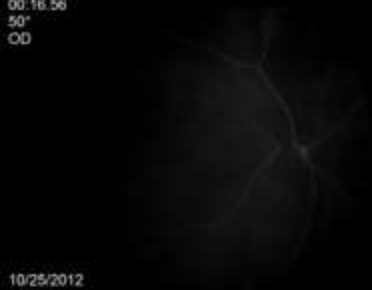- American Uveitis Society, 1978
- No history of ocular trauma or surgery
- At least three of four signs
  - Bilateral chronic iridocyclitis
  - Posterior uveitis
  - Neurologic signs
  - Cutaneous findings



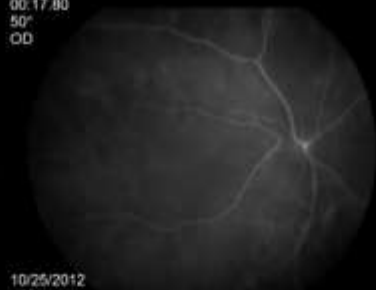



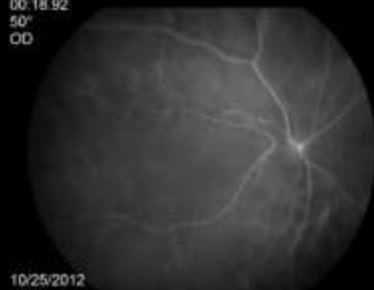
00:16.56  
50"  
OD



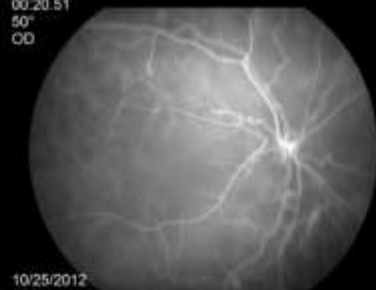00:17.80  
50"  
OD



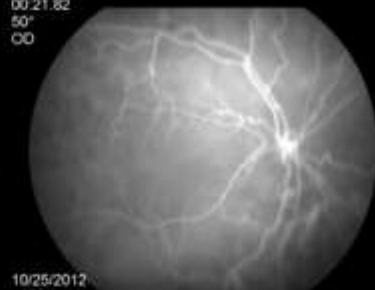
00:18.92  
50"  
OD



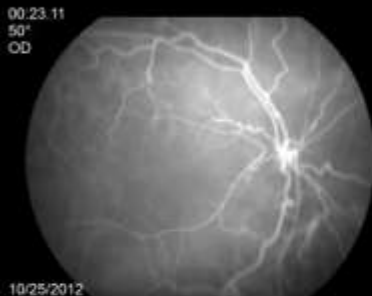00:20.51  
50"  
OD



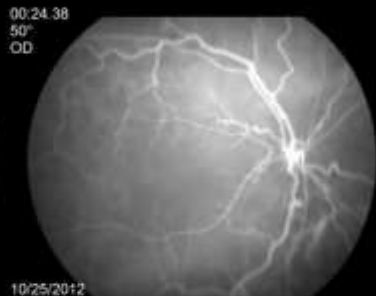00:21.82  
50"  
OD



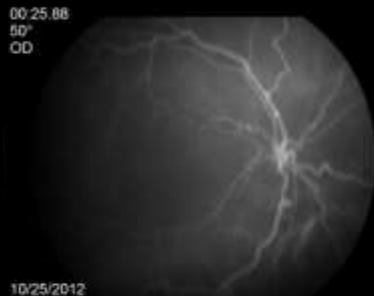10/25/2012  
21



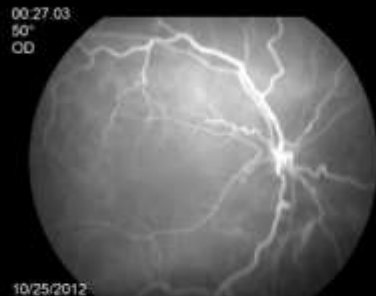10/25/2012  
22



10/25/2012  
23



10/25/2012  
24



10/25/2012  
25



00:23.11  
50"  
OD

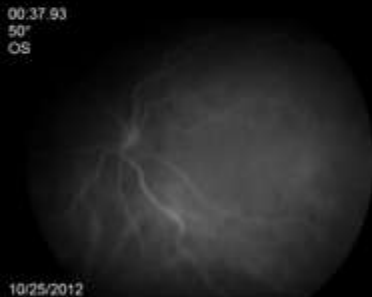
00:24.38  
50"  
OD

00:25.88  
50"  
OD

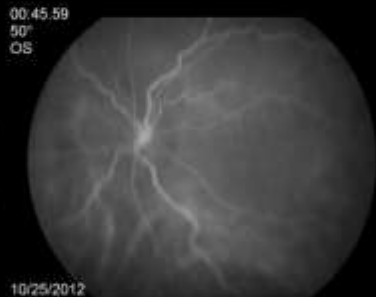00:27.03  
50"  
OD

00:31.79  
50"  
OS

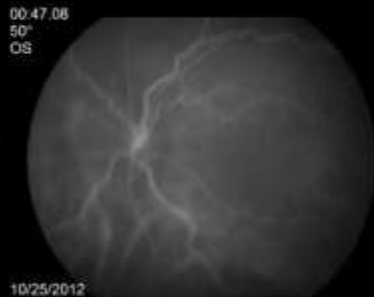
10/25/2012  
26



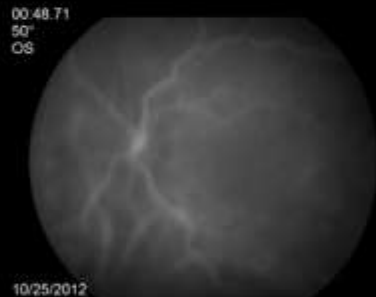
10/25/2012  
27



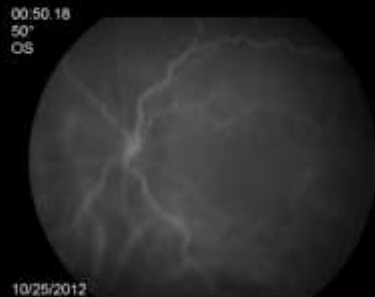10/25/2012  
28



10/25/2012  
29



10/25/2012  
30



00:37.93  
50"  
OS

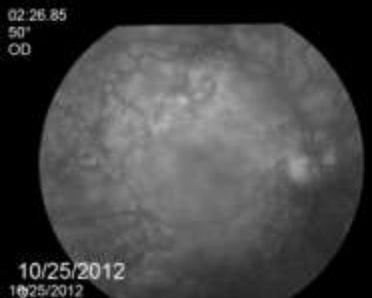
00:45.59  
50"  
OS

00:47.08  
50"  
OS


00:48.71  
50"  
OS

00:50.18  
50"  
OS


10/25/2012  
31




10/25/2012  
32




10/25/2012  
33



10/25/2012  
34



10/25/2012  
35



02:26.85  
50"  
OD

02:29.15  
50"  
OD

02:32.97  
50"  
OS

02:35.15  
50"  
OS

02:37.24  
50"  
OS


10/25/2012  
36



10/25/2012  
37



10/25/2012  
38



10/25/2012  
39



10/25/2012  
40



